



The Temporal Bone

Dr K Lehmann

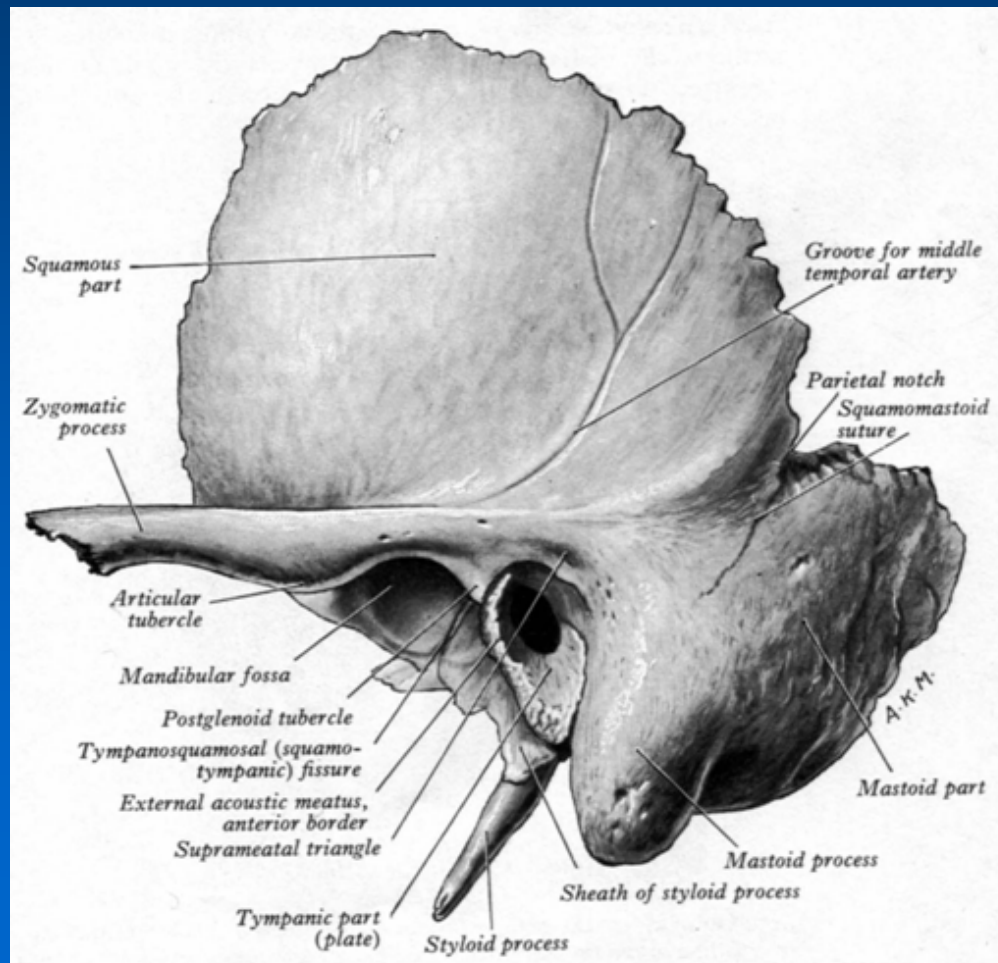
Division of Otorhinolaryngology

University of Stellenbosch and Tygerberg
Hospital

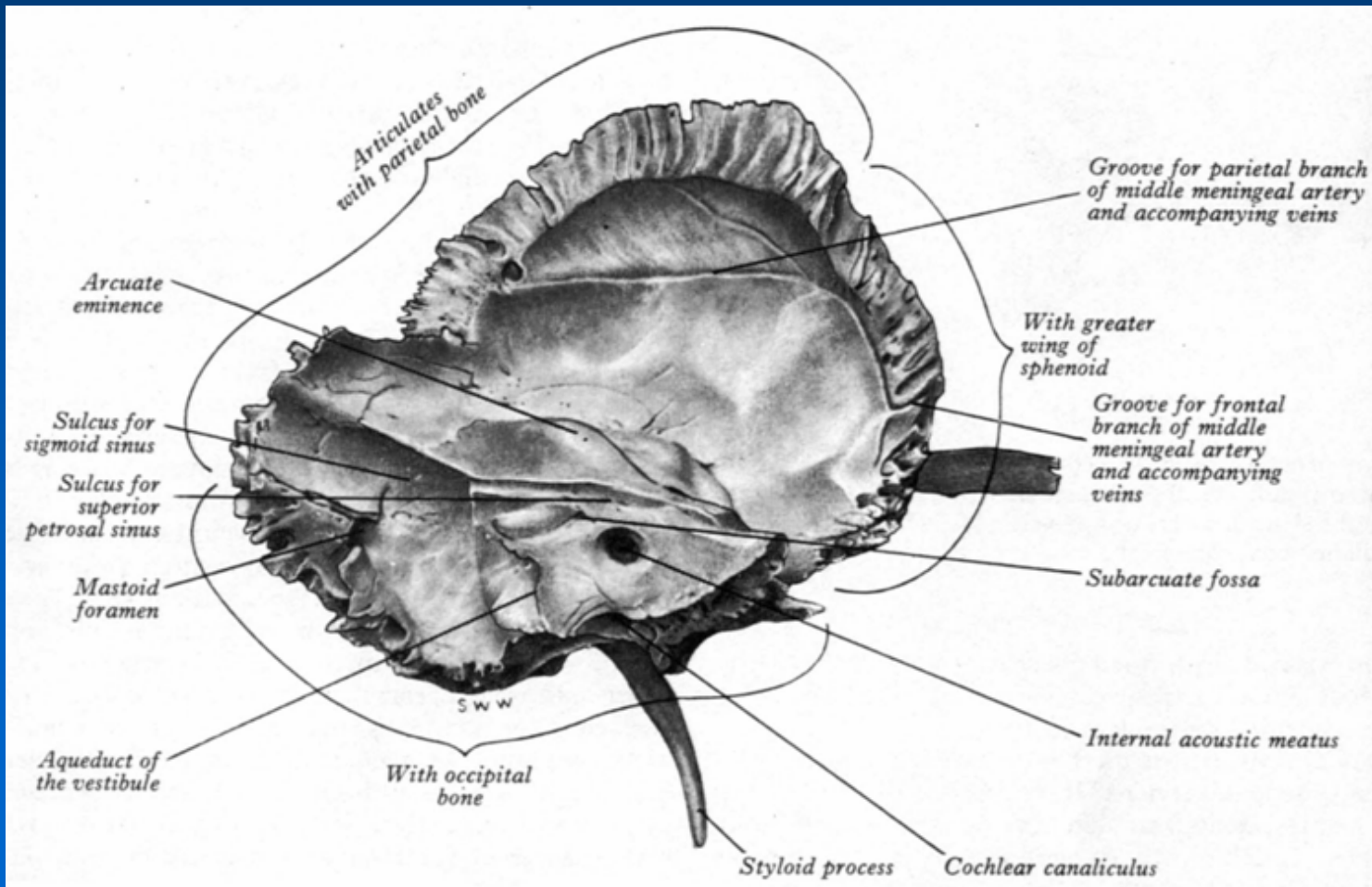
Four elements fuse to form temporal bone

- Petromastoid
- Squamous
- Tympanic
- Styloid process

Temporal bone



Temporal bone



Petromastoid

- Petrous (G: Petra: Rock)
- Derived from the petrous bone
- Dense, bony mass
 - Ossification of cartilagenous otic capsule
 - 16th week (embrio)
 - No suture lines

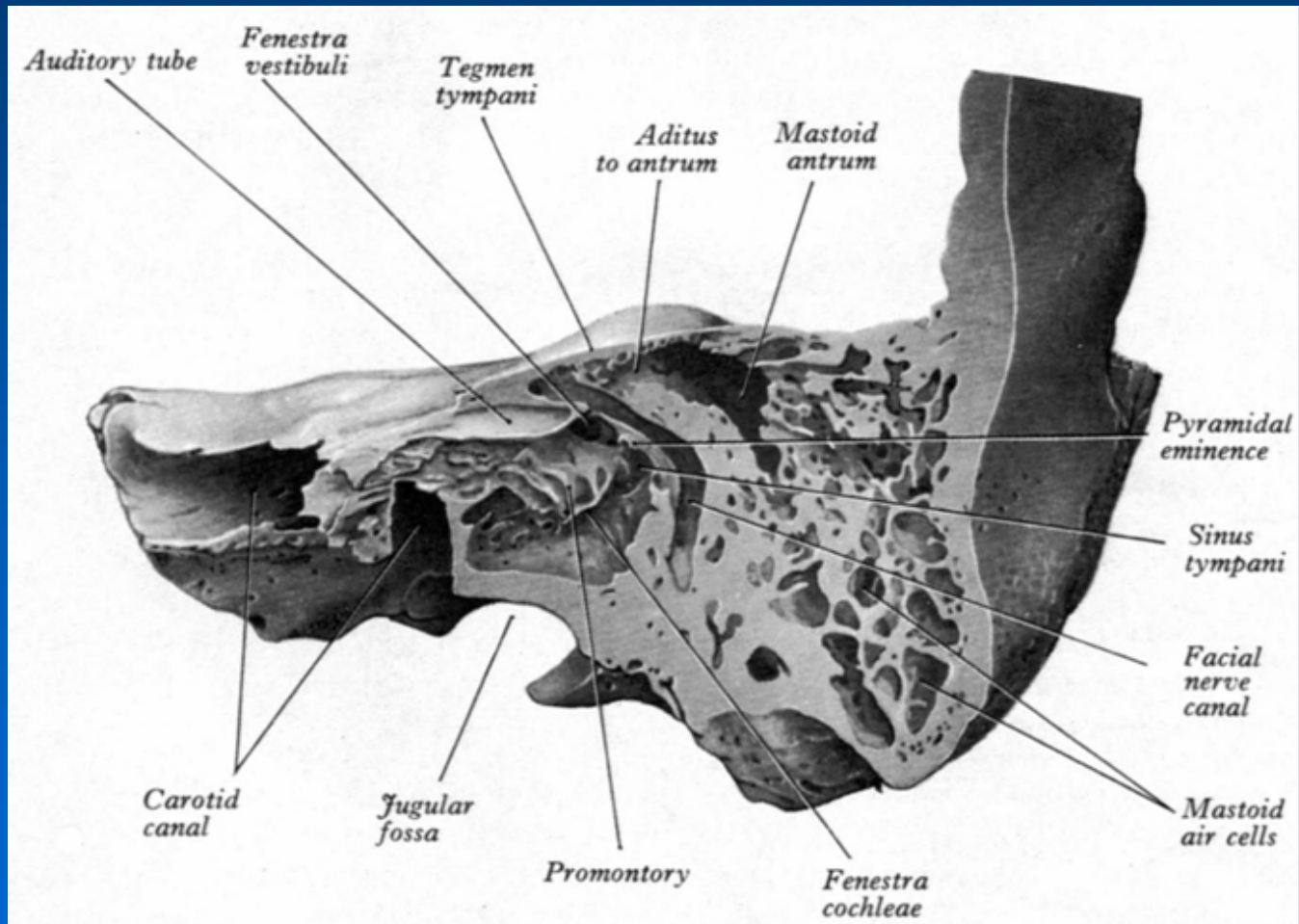
Petromastoid *(continued)*

- Contains important structures:
 - Inner ear (labyrinth)
 - Cochlea, semi-circular canals
 - Internal acoustic meatus
 - Facial nerve, vestibulo cochlear nerve, (superior and inferior), intermediate nerve, internal auditory artery and vein)
 - Canal for facial nerve
 - Fallopian canal
 - Mastoid air cells

Petromastoid *(continued)*

- Forms:
 - Roof and floor of middle ear
 - Lateral half of Eustachian tube
 - Base of skull

Petromastoid



Squamous

- Starts to ossify from a single centre at root of zygoma
- 8th week (embryo)
- Posterior inferior part grows down behind the tympanic ring
 - Forms lateral wall of fetal mastoid antrum

Tympanic

- Starts to ossify from several centres around the external meatus
- Forms a ring with a groove → sulcus for tympanic membrane (annulus)
- Contains the bony passage from the auricle:
 - The external acoustic meatus

Styloid process

- Slender, pointed bone
- Not fully developed at birth
- Gives attachment to certain ligaments and muscles (eg stylohyoid muscle, posterior belly of digastric muscle)
- Lies next to stylomastoid foramen: facial nerve

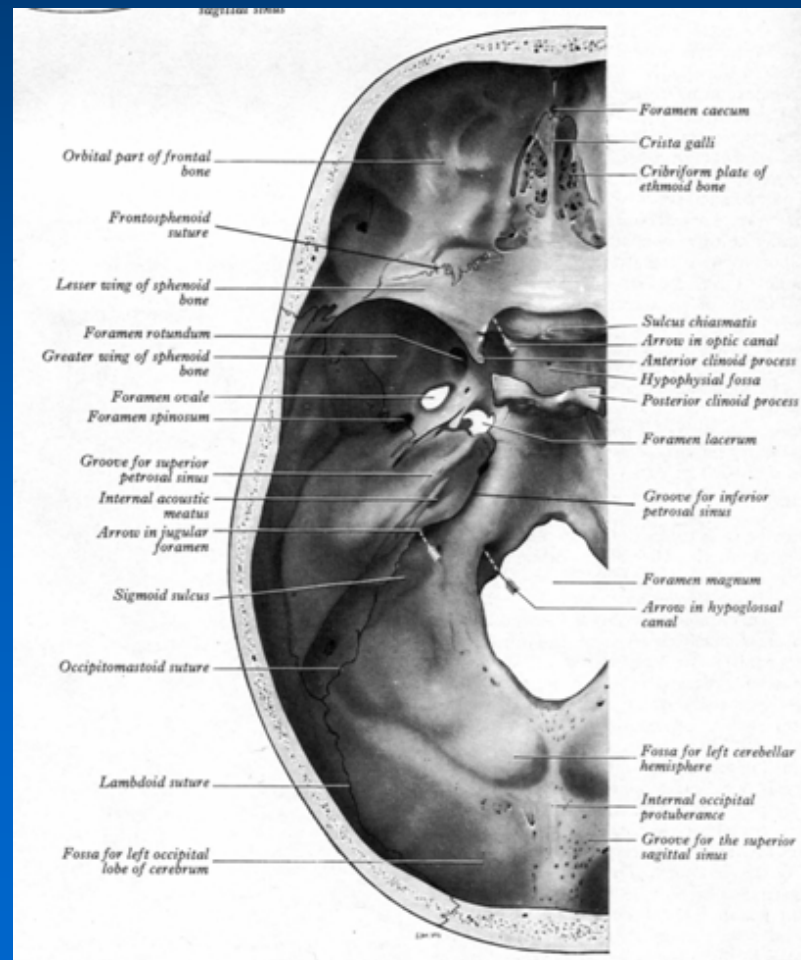
Temporal bone (articulation; processus)

- Articulates at sutures with parietal, occipital, sphenoid and zygomatic bones
- Zygomatic process of temporal bone unites with temporal process of zygomatic bone to form zygomatic arch
- Zygomatic process of temporal bone articulates with head of mandible at mandibular fossa
- Zygomatic arches: widest parts of face, commonly fractured and depressed

Cranial fossae

- Anterior, middle and posterior (largest)
- Lodges various parts of the central nervous system
- Anterior:
 - Frontal lobes of cerebral hemispheres
- Middle:
 - Anterior extremities of temporal lobes (temporal poles); and half of inferior surface of temporal lobe
- Posterior:
 - Cerebellum, pons and medulla

Cranial fossae



Posterior cranial fossa

- Formed largely by the inferior and anterior parts of occipital bone
- Also:
 - Body of sphenoid
 - Petromastoid part of temporal bone
- Tentorium cerebelli covers the cerebral hemispheres and the occipital lobes lie on the tentorium cerebelli, superior to the posterior cranial fossa

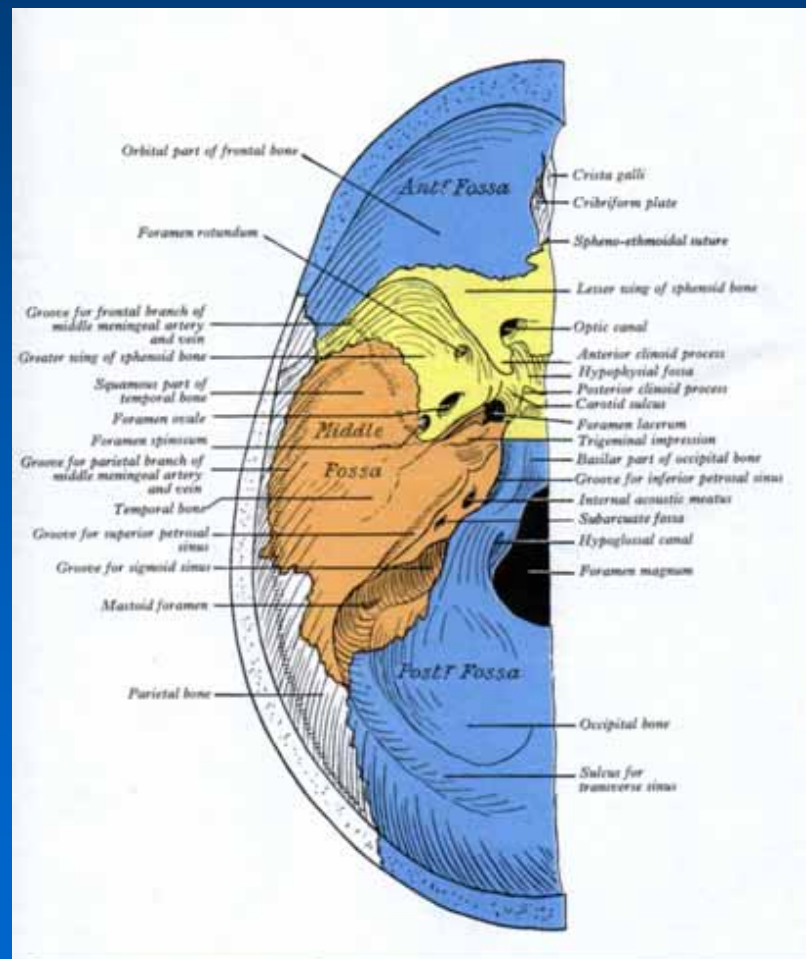
Cranial foramina

- Many foramina (l. openings) perforate the base of skull
- Mostly they are for the passage of the twelve cranial nerves (some are for bloodvessels)
- Presence of all the foramina and thin areas of bone in the cranial floor make the skull base fragile and vulnerable to fracture and to invasion by malignancy (primary or metastatic disease)

Foramina

- Anterior cranial fossa:
 - Cribriform plate: axons of olfactory cells
- Middle cranial fossa:
 - Sphenoid bone and petrous part – temporal bone
 - Most foramina found in sphenoid bone, but cranial nerves found close to petrous part of temporal bone

Foramina



Middle cranial fossa *(continued)*

- Crescent of foramina found in the greater wing of sphenoid:

Four constant foramina:

- Superior orbital fissure: communication between middle cranial fossa and orbit
 - CN III, IV, VI
 - Frontal nerve (CN V¹)

Middle cranial fossa *(continued)*

- Foramen rotundum:
 - Maxillary nerve (CN V²)
- Foramen ovale:
 - Mandibular nerve (CN V³)
- Foramen spinosum:
 - Middle meningeal artery (largest)

Middle cranial fossa *(continued)*

- The foramen lacerum is located between base of sphenoid and apex of petrous part of temporal bone
- Contains the internal carotid artery

Posterior cranial fossa

- Foramen magnum:
 - Largest
 - Unpaired
 - Junction of medulla and spinal cord
- Usually oval-shaped
- Lies at most inferior part of middle cranial fossa, midway between the mastoid processes
- CN XI: spinal roots

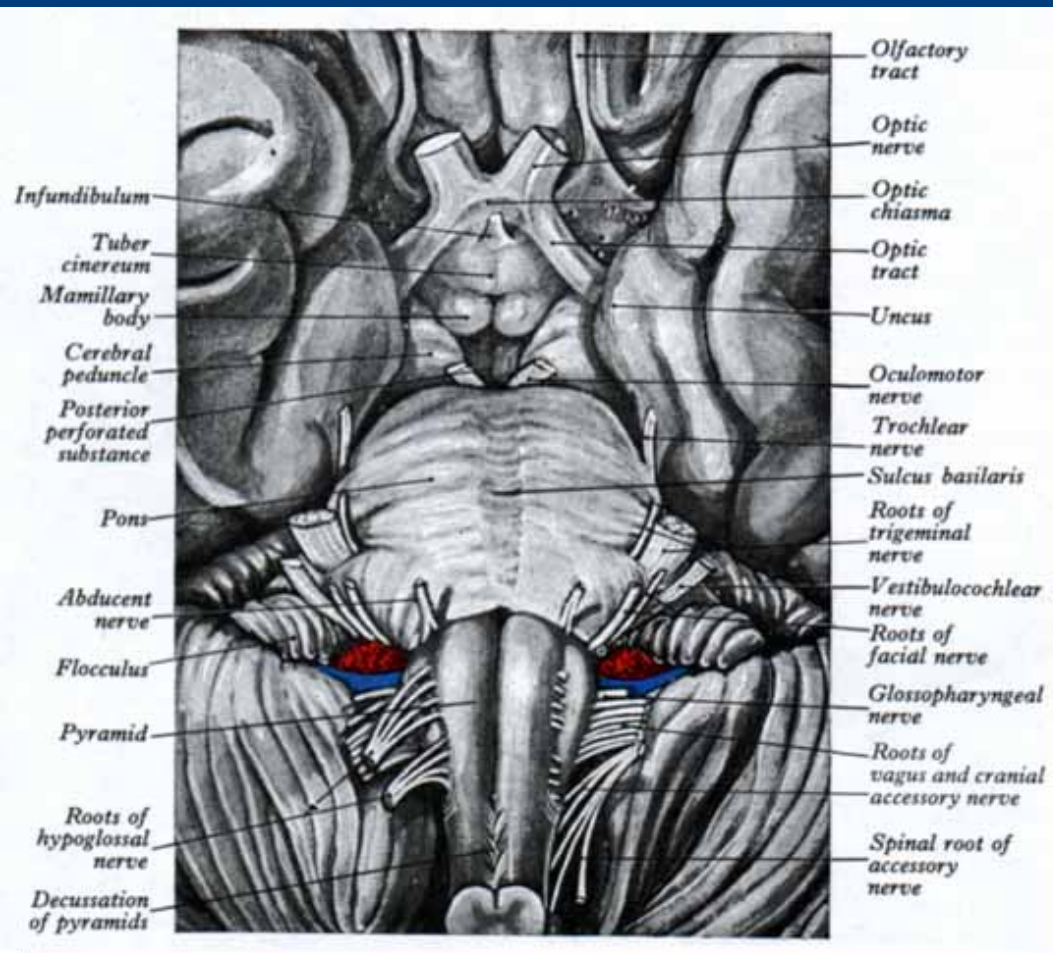
Posterior cranial fossa *(continued)*

- Jugular foramen:
 - Between occipital bone and petrous part of temporal bone
 - CN IX (glossopharyngeal nerve)
 - CN X (vagus nerve)
 - CN XI (accessory nerve)
- Superior bulb of internal jugular vein. Contains the tympanic body: chemoreceptor tissue.
Tumour → cause symptoms owing to neighbouring cranial nerves

Posterior cranial fossa *(continued)*

- Hypoglossal foramen:
 - CN XII (hypoglossal nerve)

Posterior cranial fossa



Summary

- Temporal bone: four parts
- Houses important structures
- Petrous part:
 - Hardest bone in body
 - Contains inner and middle ear
 - Adult size at birth
 - Thus cochlea is adult size at birth

Summary *(continued)*

- Cranial nerves run through foramina; skull base susceptible to fractures and infiltration by malignancy
- Clinically:
 - CN fall out might be only sign of pathology
 - If clinically suspected; can be visualized by CT/MRI
- Must be able to test for cranial nerve function and make connection

Examples

- CN IX; X; XI fall out; and pulsatile tinnitus: glomus jugulare
- CN V; VI fall out; pain: Gradenigo syndrome: malignant otitis externa
- CN VII; VIII: temporal bone fracture
- CN VIII: unilateral: acoustic neuroma
- CN V; VI; in patient with prostate CA: metastatic disease to petrous apex