

Departmental Guidelines - EPISTAXIS

Epistaxis - bleeding from the nose

One of Otolaryngology's commonest and most difficult emergencies

Historically - the simplest treatment for a nosebleed (pinching the ala nasi) is called the Hippocratic technique.

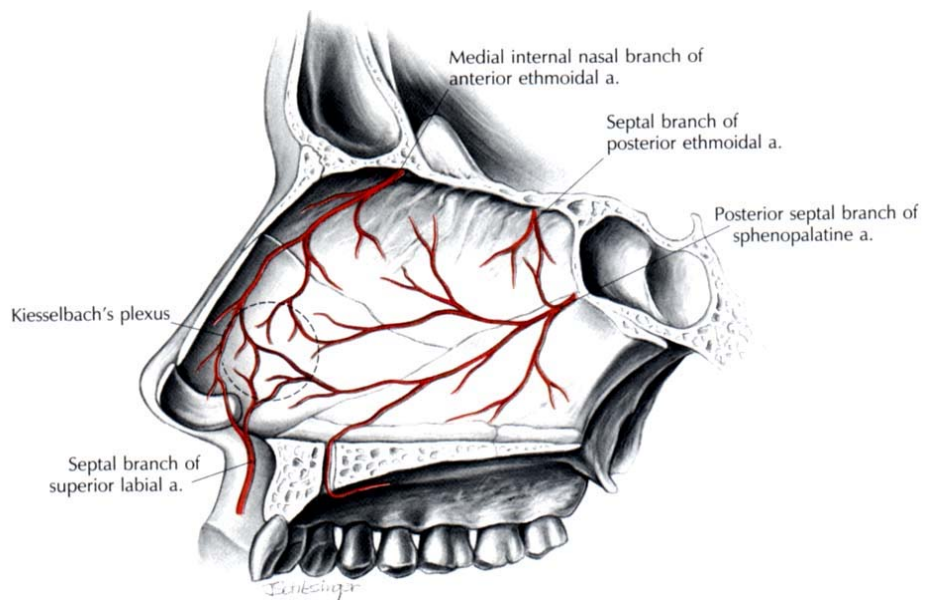
ANATOMY

Arterial Supply

ICA and ECA supply nose via branches anastomosing within the lateral wall, septum and across the midline.

Anterior septum - area most frequently implicated in epistaxis is known as Little's area or Kiesselbach's Plexus.

Posterior nasal cavity - vessels are larger than those in Little's area and can more easily be traced to their ECA or ICA origin.



External Carotid Artery (ECA)

Supplies the nasal cavity via facial and maxillary branches.

Facial artery supplies most anterior part of the septum (septal rami of superior labial a.), the vestibule (lateral nasal a.) and small area of the nasal cavity (ascending palatine a.).

Maxillary artery supply is via sphenopalatine and greater palatine branches.

Greater palatine supplies the antero-inferior part of the nasal floor and septum

Sphenopalatine is an important supply to the nasal cavity
It enters through the sphenopalatine foramen and immediately divides into **posterior septal** and **posterior lateral** branches.

Posterior lateral → inferior and middle turbinate arteries.

(Inferior and middle turbinate arteries run in bony tunnels within the turbinates.)

Posterior septal → runs medially across the face of the sphenoid to the posterior part of the septum then takes a course antero-inferiorly in the muco perichondrium to anastomose in Little's area.

Internal Carotid Artery (ICA)

Contributes the anterior and posterior ethmoidal branches of the ophthalmic artery.

Anterior ethmoidal arises in the orbit, runs under the superior oblique muscle to the anterior ethmoidal canal in which it traverses the ethmoid and nasal cavities and terminates in the region of the ethmoid fovea in a meningeal branch and a larger branch to the nasal roof, olfactory cleft and superior turbinate.

Posterior ethmoidal runs medially and passes above the superior oblique muscle to enter the posterior ethmoidal foramen situated 5mm anterior to the optic canal and 10-15mm behind the anterior ethmoidal foramen. It divides into a terminal meningeal branch and a branch to the postero-superior nasal cavity, olfactory sulcus and sphenoidal recess.

Internal and External Carotid Territories

The nasal cavity is the location of the principal internal-external carotid artery anastomoses in the head and neck. There has been debate over the relative importance of each supply to the nasal cavity.

The view that the middle turbinate marks the watershed between internal and external carotid circulations is erroneous as the arterio-arteriolar anastomotic network allows varying directions of flow to occur.

Compensatory anastomotic flow via facial arteries is thought to explain re-bleeding which may occur following ligation or embolisation.

Key clinical areas

Woodruff's Plexus

The role of Woodruff's Plexus in epistaxis is frequently discussed. It is a plexus of prominent blood vessels inferior to the posterior end of the inferior turbinate, a frequent site of adult epistaxis and so-called "posterior" epistaxis. Recent study with endoscopic photography and anatomical micro-dissection confirms the existence of the plexus and confirms that it is a venous plexus.

Lateral wall or Septal Bleeding?

There is general acceptance that most epistaxis occurs from Little's area but there is debate on the relative importance of various other sites.

Some suggest that Woodruff's plexus is important
Others nominate the septum or other regions of the lateral wall as prime sites.

Literature supports the observation that posterior, like anterior, epistaxis is predominantly septal in origin.

CLASSIFICATION OF EPISTAXIS

A clinical classification based on the patterns of presentation of epistaxis is useful

There is a pronounced bimodal distribution in the age of onset of epistaxis:

common in childhood - less common in early adult life - peaks again in 6th decade

Thus, while it can occur at any time in life, this variation with age is sufficiently pronounced to classify epistaxis as

- childhood** (less than 16years) or
- adult** (greater than 16 years).

Between 70% and 80% of all cases of epistaxis are idiopathic, spontaneous bleeds without any proven precipitant or causal factor.

This type of bleeding can be classified as **primary** epistaxis.

A small proportion are due to a clear and definite cause such as trauma, surgery or anti-coagulant overdose and can be classified as **secondary** epistaxis.

The distinction between primary and secondary epistaxis is more than academic as the management of each type is quite different e.g. techniques used to control primary epistaxis are unlikely to be successful for secondary epistaxis due to coagulopathy.

The terms **anterior** and **posterior** epistaxis are frequently used but their definitions are imprecise and inconsistent.

Anterior epistaxis - bleeding from a source anterior to the plane of the piriform aperture. This includes bleeding from the anterior septum and rare bleeds from the vestibular skin and muco-cutaneous junction.

Posterior epistaxis – bleeding from a vessel situated posterior to the piriform aperture. This allows further sub-division into lateral wall, septal and nasal floor bleeding

ADULT PRIMARY EPISTAXIS

Mainly a disease of the elderly.

The peak presentation is the 6th decade

Most cases are minor, self-limiting or easily managed anterior bleeds but nevertheless a significant number require admission to hospital.

Aetiology

By definition the aetiology of primary epistaxis is unknown but there are clear suggestions that systemic factors may be important.

- **Non-steroidal anti-inflammatory drugs (NSAID)**. Adult pattern epistaxis is associated with the use of NSAID. Patients are more likely than controls to consume NSAID. The NSAID used include prescribed and self-administered compounds especially aspirin.
- **Alcohol**. Similar aetiological associations to those of NSAID have been found with alcohol. Epistaxis patients are more likely to consume alcohol than matched control patients and are more likely to have consumed alcohol within 24 hours of hospital admission than other emergency admissions
- **Hypertension**. A number of large studies have failed to show a causal relationship between hypertension and epistaxis. Even if not causal, elevated blood pressure is observed in almost all epistaxis admissions. This apparent hypertension in acute admissions may be a result of anxiety associated with hospital admission and the invasive techniques used to control the bleeding.

Management

Effective management of adult epistaxis follows a step-wise sequence of interventions.

Theoretically → identification of the bleeding point and direct control of the bleeding.

First, the patient must be resuscitated, bleeding slowed, the nasal cavity examined and a treatment plan established.

Resuscitation

Given the high prevalence of co-existent cardiovascular disease, prompt and effective resuscitation is required.

First aid by pinching the ala nasi is supported by the frequency with which the anterior part of the septum is the source of bleeding.

History and examination will help in assessing the amount of blood lost.

In any other than minor bleeds intravenous access should be established and baseline blood estimations taken.

A detailed history should be taken, looking for predisposing factors

Assessment

The patient should be assessed with nursing assistance and everyone involved should wear protective visors and clothing as blood aerosol contamination is common, especially when inserting nasal packing.

Basic equipment includes:

- couch or reclining chair
- headlight
- suction
- vasoconstrictor solutions (lignocaine & pseudoephedrine or cocaine)
- selection of packs/tampons
- cautery apparatus
- rod lens nasal endoscopy equipment
- bipolar electrodiathermy

Direct or Indirect therapies

Treatment may be divided into direct (bleeding point specific therapies) or indirect treatments, which do not require identification of the bleeding point. Direct treatments are logically and theoretically superior and, therefore, a committed search for the bleeding vessel should be undertaken

Direct Management

Anterior epistaxis is usually very straightforward to locate and treat and at present over 90% of cases are controlled with silver nitrate cautery

The use of packing for primary anterior epistaxis is unwarranted and should be discouraged.

Posterior epistaxis can occur from the lateral wall, floor or septum

Systematic examination with a headlight will identify most bleeding points.

Once identified, bleeding points can be directly controlled with bipolar diathermy, chemical cautery (difficult in posterior bleeds), electro cautery, or direct pressure from miniature packs.

Endoscopic control

Failure to locate the bleeding point on initial examination is an indication for examination with a rod lens endoscope

Endoscopy identifies the source of posterior epistaxis in over 80% of cases

Endoscopy enables targeted haemostasis of the bleeding vessel using insulated hot wire cautery or modern single fibre bipolar electrodes

Success rates for immediate control by endoscopic guidance are consistently reported in the 90% range

Monopolar diathermy should not be used in the nasal cavity as there have been reports of blindness due to current propagation

Adoption of direct (including endoscopic) management strategies has been shown to facilitate out-patient management and to significantly reduce in-patient stay.

Indirect Therapies

Failure to find the bleeding point is an indication for use of one of numerous traditionally favoured indirect strategies.

Nasal Packing

Packing can be anteriorly or posteriorly placed.

Ribbon gauze impregnated with bismuth iodoform paraffin paste (BIPP) is inserted the entire length of the nasal cavity in attempt to tamponade the bleeding. Once inserted, the packs are left in situ for between 24 and 72 hours.

Complications of packing include; sinusitis, septal perforation, alar necrosis, hypoxia and myocardial infarction. Packing is usually considered an indication for antibiotic cover

Modern variations on anterior packing include special tampons and balloon catheters.

Persistent bleeding or re-bleeding is an indication for further examination of the nasal cavity and renewed search for the bleeding point - patients who continue to bleed should proceed to surgical management sooner rather than later.

Posterior nasal packs

Posterior packing can be carried out under local anaesthetic

Nasopharyngeal tamponade is achieved using a Foley urethral catheter (size 12 or 14) inserted along the floor of the nasal cavity until the nasopharynx is reached. The Foley catheter is inflated with 15mls of water, pulled forward to engage in the posterior choana and anterior packing is then inserted. The Foley catheter needs to be secured anteriorly taking care not to cause pressure over the columella. Posterior packing causes considerable pain and may cause hypoxia secondary to soft palate oedema. Sinusitis and middle ear effusions are common. More serious complications include necrosis of the septum and columella. Antibiotics and analgesia are necessary. Posterior packs should be left in position for a minimum of 12 hours.

Systemic medical therapy

Tranexamic acid and epsilon aminocaproic acid are systemic inhibitors of fibrinolysis.

Tranexamic acid has been shown to reduce the severity and risk of rebleeding in epistaxis at a dose of 1.5 grammes three times a day. These drugs do not increase fibrin

deposition and so do not increase the risk of thrombosis. Pre-existing thromboembolic disease is a contraindication. At present anti-fibrinolytics are best reserved as adjuvant therapy in recurrent or refractory cases.

Surgical Management

If the techniques described above fail, surgical intervention is required.

Endoscopic diathermy of the bleeding point under anaesthetic may control the bleeding but if the vessel still cannot be controlled (or even located) indirect surgical therapy is indicated. Surgical management for continued epistaxis consists of:

- Ligation techniques
- Septal surgery techniques
- Embolisation techniques.

Ligation techniques

Ligation is reserved for intractable bleeding where the source cannot be located or controlled by the techniques described above. Knowledge of the blood supply of the nasal cavity and the likely sources of epistaxis will inform the choice of ligation technique.

Ligation should be performed as close as possible to the likely bleeding point thus the hierarchy of ligation is:-

- Sphenopalatine Artery
- Internal Maxillary artery
- External Carotid artery
- Anterior /posterior Ethmoidal artery

Endonasal Sphenopalatine artery ligation (ESPAL)

ESPAL conforms to the ideal of controlling the bleed as close as possible to its nasal source. Once the main vessel is identified, it can be ligated using haemostatic clips and divided or coagulated using bipolar diathermy. Complications including re-bleeding (anastomoses), infection and nasal adhesions are generally less common than with other procedures.

Internal Maxillary artery ligation (IMAL)

This was more frequently used prior to the development of ESPAL procedures. The artery is exposed trans-antrally and identified prior to clipping with haemostatic clips. An endoscopic variation on this technique uses a middle meatus antrostomy as an instrument port with a 4mm endoscope is inserted through a small canine fossa antrostomy. Complications include: sinusitis, damage to the infra-orbital nerve, oro-antral fistula, dental damage and anaesthesia and rarely ophthalmoplegia and blindness.

External carotid artery ligation (ECAL)

ECAL represents a step further away from the nasal source of bleeding. This procedure can be carried out under local or general anaesthetic using either a skin crease incision or a longitudinal incision parallel with the anterior border of the sternocleidomastoid. The carotid bifurcation is identified and the external carotid confirmed, double-checked for

arterial branches and then ligated in continuity. Complications include, wound infection, haematoma and neurovascular damage.

Anterior/posterior ethmoidal artery ligation (EAL)

Given the minimal contribution of these arteries to the nasal blood supply, their ligation is best reserved as an adjuvant to one of the procedures described above or in cases of confirmed ethmoidal bleeding (e.g. ethmoidal fracture, iatrogenic tear). The arteries are approached by a medial canthal incision that is carried down to the bone of the anterior lacrimal crest. The vessel is clipped and divided and dissection is continued to identify the posterior artery which is located approximately 12mm behind

Septal surgery

When epistaxis originates behind a prominent septal deviation or spur, septoplasty or submucosal resection may be required for access to the bleeding point. Some authors have advocated septal surgery as a primary treatment for failed packing. The rationale is that by elevating the mucoperichondrial flap for septoplasty or SMR, the blood supply to the septum is interrupted and haemostasis secured

Embolisation

Once the bleeding vessel is identified, a fine catheter is passed into the internal maxillary circulation and particles (poly vinyl alcohol, tungsten or steel microcoils) are used to embolise the vessels. The ipsilateral facial artery is also embolised in order to prevent re-circulation.

Complications include: skin necrosis, paraesthesia, cerebrovascular accident and groin haematomas.

Embolisation is of similar efficacy to ligation techniques and, therefore, choice will depend on local expertise, availability and experience.

SECONDARY EPISTAXIS

Epistaxis is commonly observed in patients with coagulopathy secondary to liver disease, leukemia or myelosuppression. In such cases, treatment of the epistaxis demands **close** liaison with haematologists and physicians. The following causes of secondary epistaxis deserve special mention.

Trauma

Post traumatic nasal haemorrhage does not conform to the normal pattern of epistaxis and its origin and severity is almost infinitely variable. Persistent bleeding can occur from the ethmoidal arteries following fronto-ethmoidal fracture. In this case the vessels may be lacerated, incompletely divided or even held open by fractures through their bony mesenteries. Severe haemorrhage refractory to packing should be managed by open approach ligation after reduction of displaced fractures if appropriate.

Post surgical

Bleeding can occur after almost any nasal surgery and is seldom difficult to manage.

Iatrogenic damage to the anterior ethmoidal artery during endoscopic sinus surgery should be managed by bipolar of the vessel. Retraction of the vessel into the orbit can give rise to a tension haematoma of the orbit and is a surgical emergency. Massive and usually fatal epistaxis can result from damage to the internal carotid artery during posterior ethmoid or sphenoid sinus surgery. The bleeding is usually uncontrollable but packing, angiography and embolisation may be tried.

Warfarin

Bleeding may be due to overdose or loss of control but can also occur in patients whose INR is within the therapeutic zone.

With warfarin, direct therapies seldom work and packing may be required.

Bleeding is often from multiple sites and attempts at instrumentation lead to further mucosal damage and bleeding.

After resuscitation, anterior packs should be inserted and the haematology team consulted.

When deciding to reduce, stop or even reverse warfarin, the medical history and the severity of the epistaxis must be considered. If the INR is within the therapeutic range and treatment seems to be controlling the bleeding it may be safe to continue the warfarin.

Hereditary Haemorrhagic Telangiectasia

Hereditary Haemorrhagic Telangiectasia (HHT) or Rendu, Osler Weber disease. Recurrent epistaxis occurs in 93% of cases.

Management involves: packing, cautery, antifibrinolytics, systemic or topical oestrogens, coagulative lasers, septal dermoplasty, ligation and embolisation and as a last resort permanent surgical closure of the nostrils (Young's operation).

Tumours

Nasal tumours seldom present as epistaxis in isolation but blood stained discharge with other nasal symptoms (unilateral obstruction, pain, swelling) should alert the clinician to the possibility of carcinoma.

The risk, albeit small, of missing a tumour is another good reason for nasal endoscopy in epistaxis cases.

Juvenile Nasopharyngeal Angiofibroma (JNA) is a rare vascular tumour that can present with recurrent or severe epistaxis in association nasal obstruction. Treatment of JNA is mainly surgical but may include pre-operative embolisation.

Summary of treatment recommendations/best practice

First line _____ direct therapy (bipolar/cautery endoscopic if required)



Second line _____ indirect therapy (anterior packing)



Third line _____ Surgical therapy (endoscopic SPA ligation)



Fourth line _____ Embolisation