


# THE CAPE TEMPORAL BONE COURSE

## DISSECTION MANUAL



J.W. Looek  
G.G Browning

# CAPE TEMPORAL BONE COURSE DISSECTION MANUAL

## **General comments**

- The suggested exercises on the cadaveric temporal bone are designed to mirror standard ear surgery techniques
- The fact that they are usually performed on a non-diseased bone is a limitation at times – eg. these bones are not densely sclerotic as the bones of chronic suppurative otitis media usually are.
- Apart from standard procedures, dissections can be performed that are not normal surgical procedures. These are done to identify and learn the normal anatomy

## **Day 1 : Bone 1**

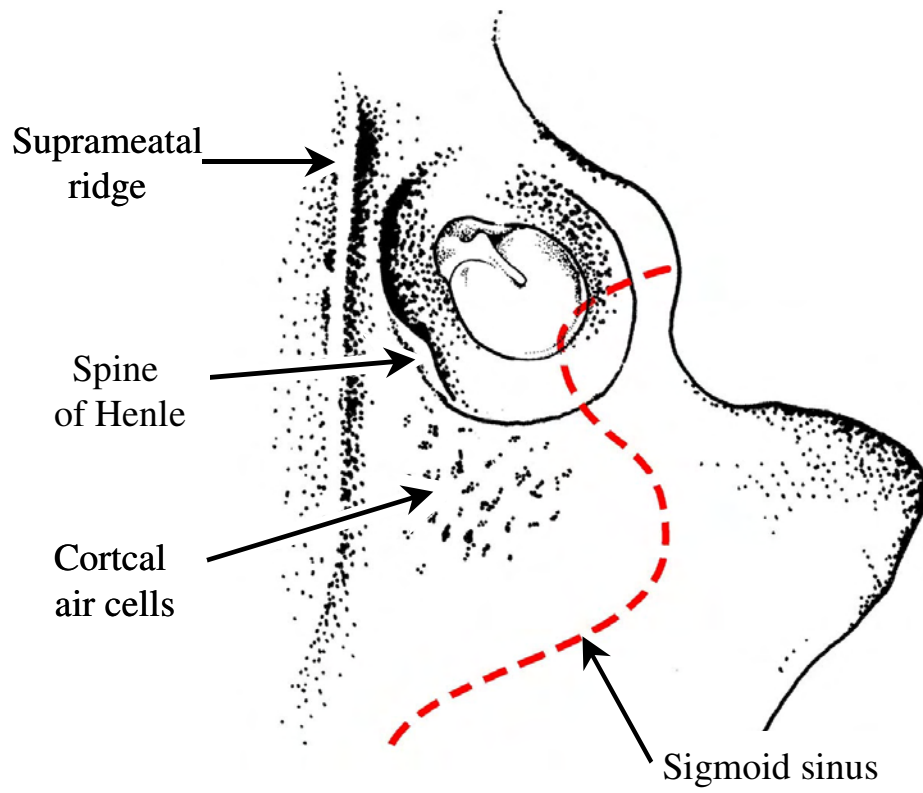
### **Setting up the microscope**

- Adjust the resistance of the joints and the balance of the microscope head
- Choose the correct lamp setting (Not the red light!)
- Check both eyes are in focus
- Check orientation of the observer arm (if present)

### **Setting up the bone**

- Identify side of chosen bone, by identifying externally the mastoid process and glenoid fossa, and internally the middle fossa and posterior fossa.
- Identify anatomy of middle and posterior cranial fossae:
  - Petrous ridge
  - Arcuate eminence
  - Internal auditory meatus
  - Sigmoid sinus
  - Hypoglossal canal
  - Niche for endolymphatic sac
  - Canal for the greater superficial petrosal nerve
- Clear soft tissue from the inferior surface of the bone and identify on it:
  - Mastoid process
  - Styloid process
  - Facial nerve exiting stylomastoid foramen
  - Digastric groove
- Strip off soft tissue from the lateral surface of the bone: the mastoid process and superior to the external auditory canal. Identify the following on the lateral surface:
  - External auditory meatus
  - Suprameatal ridge
  - Mastoid process
  - Cribriform region – the landmark on the cortex of underlying mastoid air cells
  - Henle's spine (Fig 1).
  - Picture in your mind's eye the sigmoid sinus.
- Trim off remains of cartilaginous external auditory canal and
- Fit in temporal bone holder in the surgical position
- Visualise the tympanic membrane and decide if it is normal

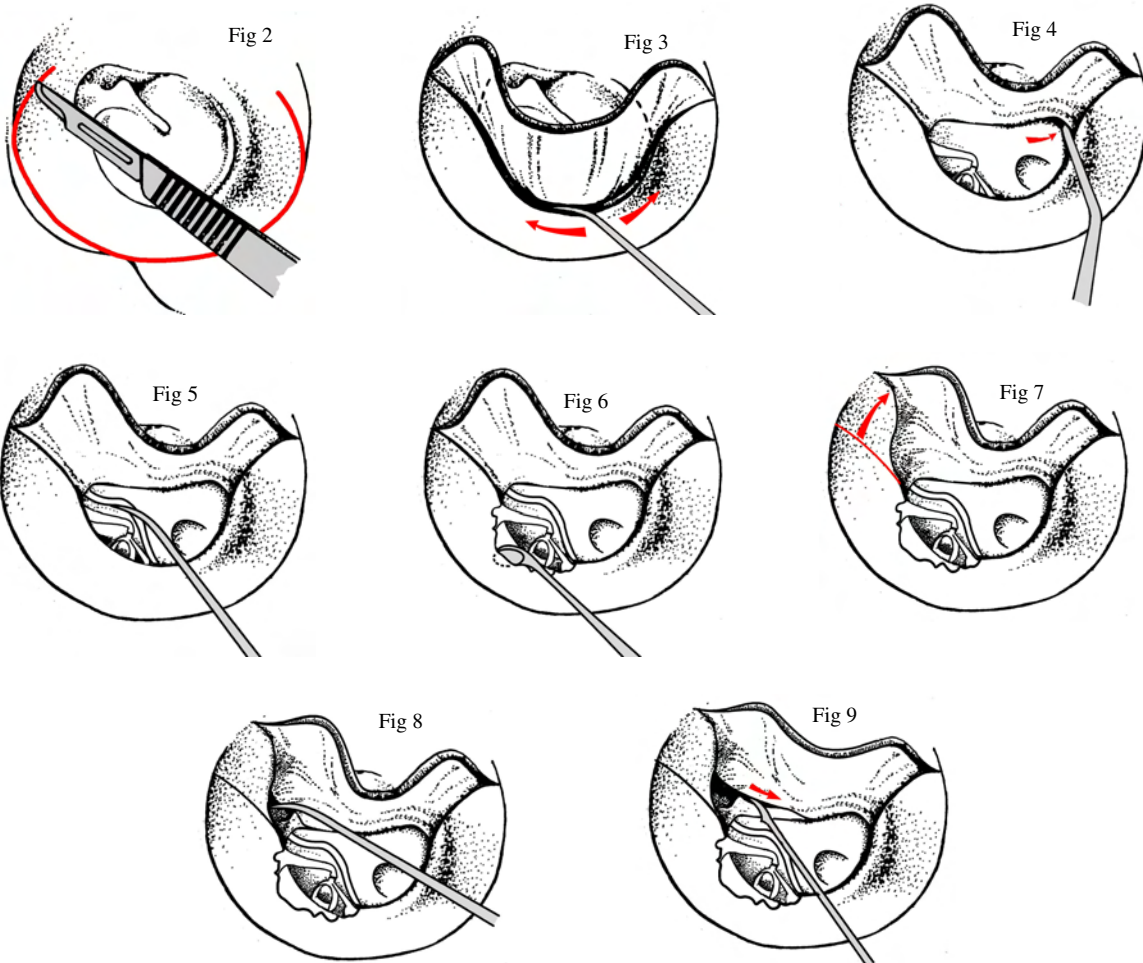
Fig 1



## Tympanotomy

This exercise aims to teach how to gain access to the middle ear through the standard posterior tympanomeatal flap approach; and how to extend this as required.

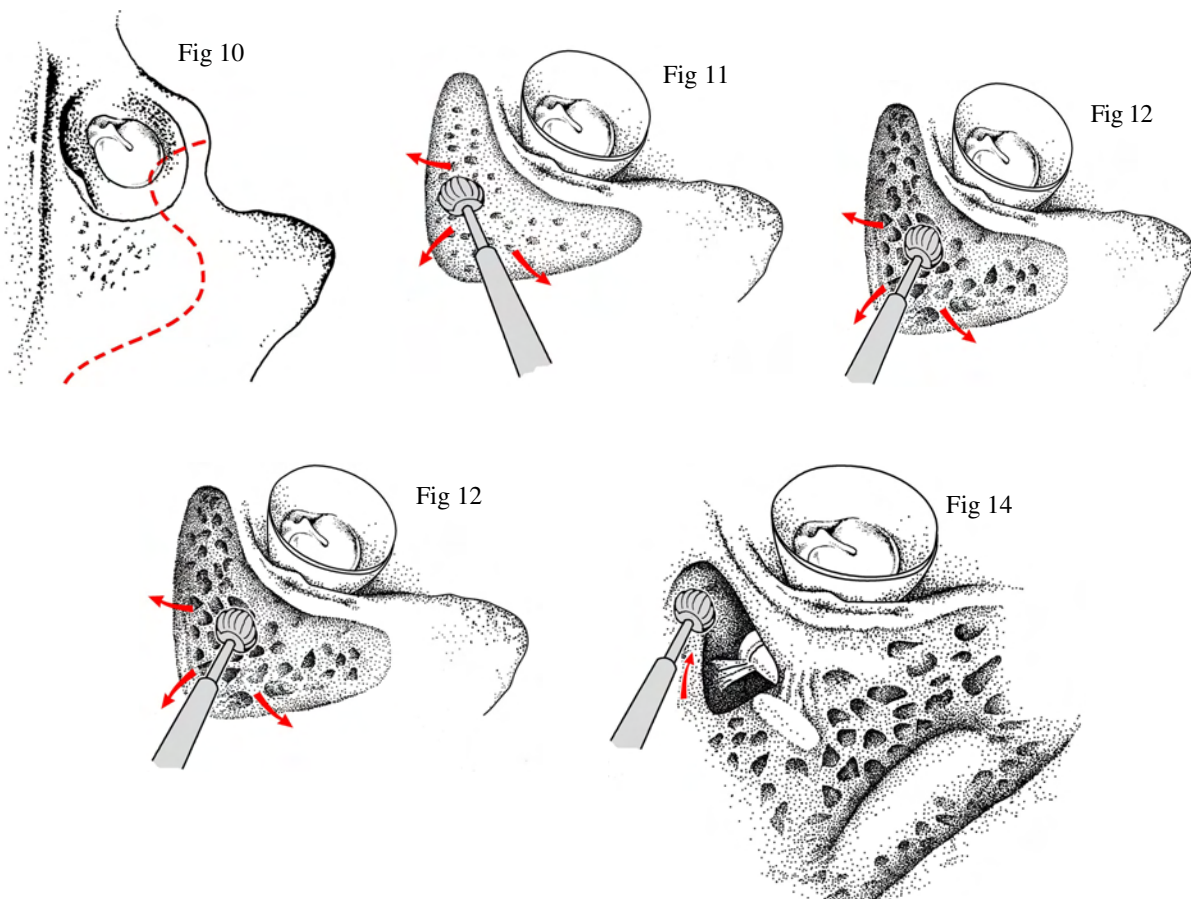
- Lift a tympanomeatal flap from 2 – 6 o' clock (R ) or 10 – 6 o' clock (L) providing standard postero-superior access (Fig 2).
- Identify the tympanomastoid suture line and release your flap from this (Fig 3).
- Dislocate the annulus from its sulcus to enter the middle ear (Fig 3). This is usually done inferiorly to avoid damaging the chorda and ossicular chain. Then elevate it inferiorly, to 6 o' clock (Fig 4), then superiorly, looking out for chorda tympani.
- Displace chorda forward. See what access you get to the posterior mesotympanum (Fig 5).
- Now curette scutum of the postero-superior canal wall to fully visualise the stapes, stapedius tendon and footplate – i.e. increase posterior access (Fig 6).
- Preserve the chorda in doing this: apart from its function it is an invaluable landmark.
- Assess the mobility of each of the ossicles without dislocating them.
- Now gain access to the anterior mesotympanum: First increase antero-superior canal access. Extend flap elevation anteriorly, freeing it off the tympano-squamous suture line (Fig 7). Then dissect the tympanic membrane off the scutum superiorly (Fig 8), and dissect the tympanic membrane off the Malleus handle from superior to inferior (Fig 9).



## Cortical mastoidectomy

This exercise takes you through the steps of an antrotomy, extending it forward to the attic, and then extending it to a full cortical mastoidectomy.

- Identify McEwans triangle: The suprameatal ridge; the external auditory canal wall; and the (theoretical) site of the sigmoid sinus (Fig 10).
- Within these landmarks create a wide, saucerised cavity with good access (Fig 11), and using safe drilling strokes from deep to shallow, follow the air cells down to the large antral air cell. Observe how the depth of its medial wall relates to that of the middle ear. When drilling use the largest cutting burr practicable and always avoid creating overhangs of bone (Fig 12,13).
- Now proceed to remove bone antero-superiorly into the attic, to expose first the incus and then the head of the malleus (Fig 14). Expose as much of the attic between dural plate and superior canal wall as aeration of this temporal bone permits. Preserve bony superior canal wall inferiorly and dura superiorly.
- Identify the lateral semicircular canal posterior to the incus (Fig 14).
- Anterior to this, imagine the position of the fallopian canal that contains the facial nerve in its horizontal and initial vertical portions, under the ossicles.
- To exenterate all the mastoid air cells:
  - Clear out air cells in the sino-dural angle
  - Skeletonise the sigmoid sinus
  - Clear remaining cells in the mastoid tip
  - Identify the digastric ridge: convex smooth bone in the mastoid tip.
- Diamond burrs are used in the areas where the facial nerve and the semi-circular canals are at risk

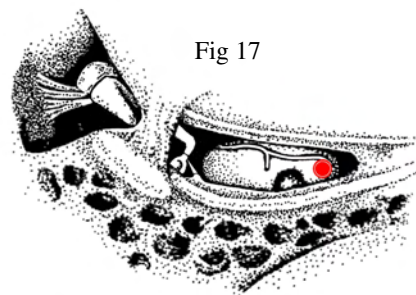
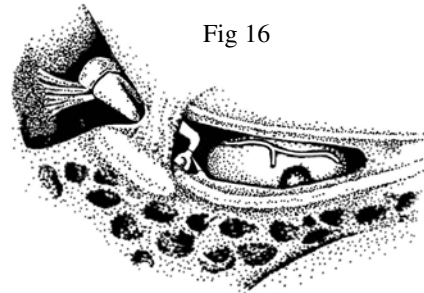
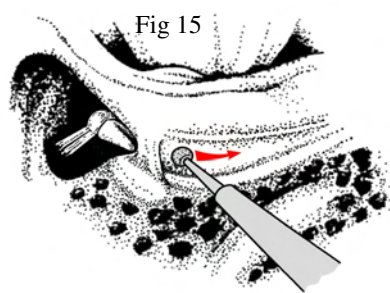


Senior dissectors may wish to proceed to

### Posterior tympanotomy

This procedure, described by Jansen for “Combined approach” for cholesteatoma in the facial recess and sinus tympani, is used in facial nerve decompression and nowadays for access to a cochleostomy in cochlear implantation.

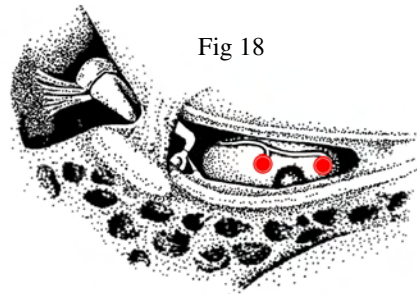
- Thin the posterior canal wall by means of combined anterior/posterior viewing. Take care not to breach the bony canal.
- Identify the incus in the incudal fossa.
- Now identify the position of the vertical portion of the facial nerve and the corda tympani coming off anterior to it. Take a 4 mm diamond burr and using light strokes over a relatively broad area inferior to the lateral semicircular canal and the “pointer” of the incus, look for the white appearance of these structures shining through their bony coverings.
- Take a 2 mm diamond burr and perform a posterior tympanotomy by using the incus as a pointer and extending the incudal fossa inferiorly between the (deeper) fallopian canal and the (more superficial) chorda tympani. Try to avoid exposing the facial nerve and chorda, and leave a thin layer of bone protecting them – as you would want to for cochlear implantation (Fig 15).
- Generally a little bridge of bone is left at the superior end to protect the short process of the incus and the posterior incudal ligament from your burr.
- Continue this until the stapes and round window niche are fully visualised (Fig 16).
- Identify the round window membrane within the round window niche, facing posterior and slightly infero-lateral. If necessary, remove the bony lip of round window niche hiding it.
- Perform a cochleostomy into the scala tympani by drilling with a 1mm and then a 0,5 mm diamond burr just inferior and slightly anterior to the round window niche. Note that the periosteum as you go through is thin and not very white. This is the correct site for an atraumatic cochleostomy (Fig 17).



Having done this, senior dissectors, if they have time, may wish to proceed to

### Scala vestibuli cochleostomy

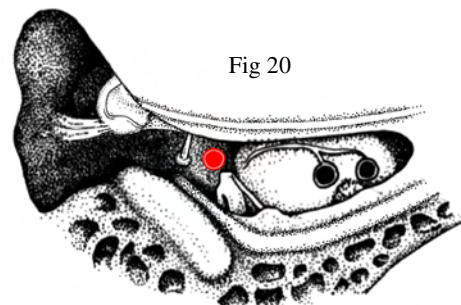
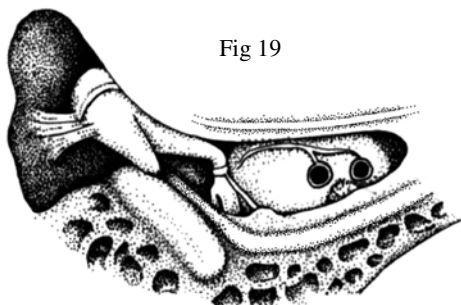
- Using a 1 mm and the 0,5 mm burr, drill a 2<sup>nd</sup> cochleostomy anterior and superior to the previous one, on the promontory inferior and slightly anterior to the stapes footplate. This enters the scala vestibuli, lying supero-lateral to the scala tympani, on the other side of the basilar membrane from your previous cochleostomy.
- Note that the periosteum here is white and thicker, where it forms the stria vascularis. A cochleostomy for cochlear implantation made here is more damaging to the basilar membrane, and used only if the scala tympani is sclerosed (Fig 18).



Having done this, senior dissectors, if they have time, may wish to proceed to

### Second turn cochleostomy

- Enlarge the superior limit of your posterior tympanotomy as much as you can between the facial nerve and the chorda tympani without damaging them, and by taking away the bony buttress at the upper limit, thus exposing the incus fully (Fig 19).
- Dislocate the incudo-stapedial joint and remove the incus.
- Remove the stapes or stapes superstructure.
- Identify the oval window, the horizontal segment of the facial nerve superior to it, and the tensor tympani tendon coming out of the cochleariform process more anteriorly under the facial nerve and deep to the malleus.
- Now drill the 3<sup>rd</sup> cochleostomy below the cochleariform process (Fig 20).
- If you look carefully you should be able to see both the scala vestibuli and the scala tympani here.
- This cochleostomy is used for insertion of the 2<sup>nd</sup> part of a “split electrode” for cochlear implantation in an ossified cochlea.

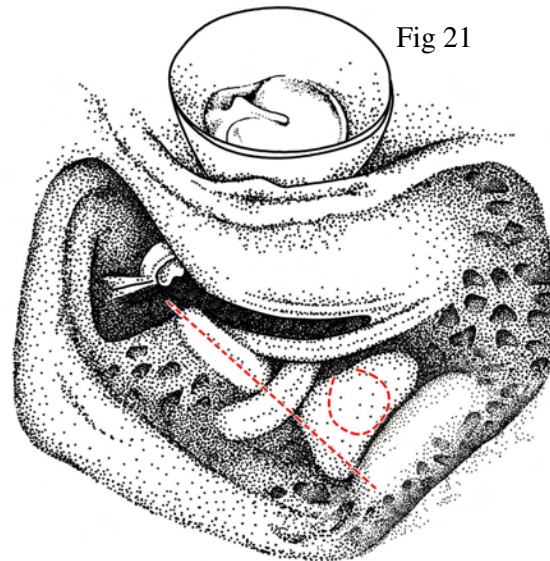


Having done this, senior dissectors, if they have time, may wish to proceed to

**Expose the endolymphatic sac (Fig 21)**

Although this surgery has little indication today, it is an interesting exercise in anatomy.

- Identify the lateral semicircular canal. If necessary, use a diamond burr to define it better.
- Use the “4mm rule” to postulate the position of the posterior canal, at right angles and 90 degrees, postero-inferior to the lateral semicircular canal, so that damage to it is avoided in subsequent drilling
- The endolymphatic sac lies posterior and inferior to the posterior semicircular canal, and anterior to the sigmoid sinus.
- To find it, using a diamond burr, expose extensively the dura anterior to the sigmoid sinus up to the posterior semicircular canal, leaving just a thin eggshell of bone.
- Now elevate the thin residual bone from the sigmoid and posterior fossa dura.
- The sac is thicker and whiter than surrounding dura and is triangular, pointing anteriorly. Nick it and see if you can identify its lumen.
- Progress as far as identifying the vestibular aqueduct exiting from its canal.



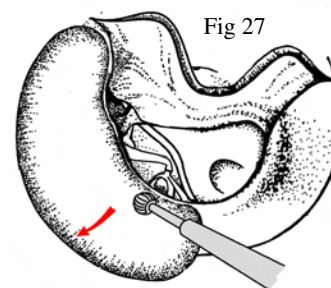
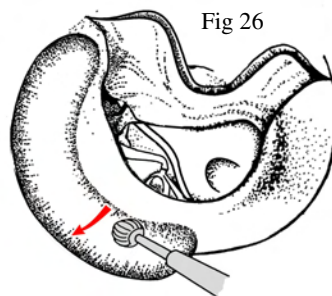
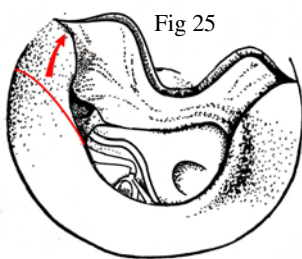
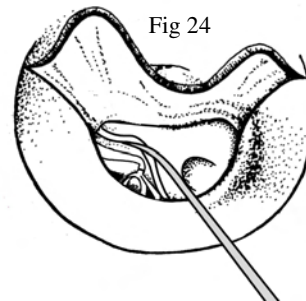
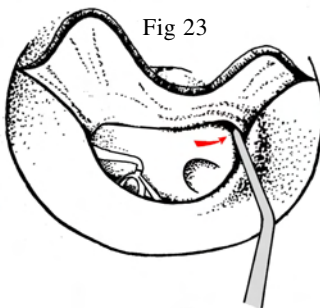
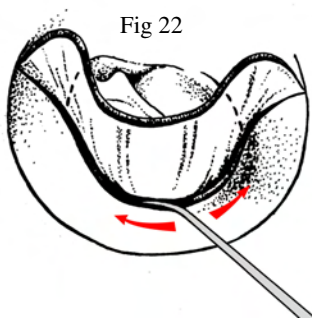


## Day 2: Bone 2

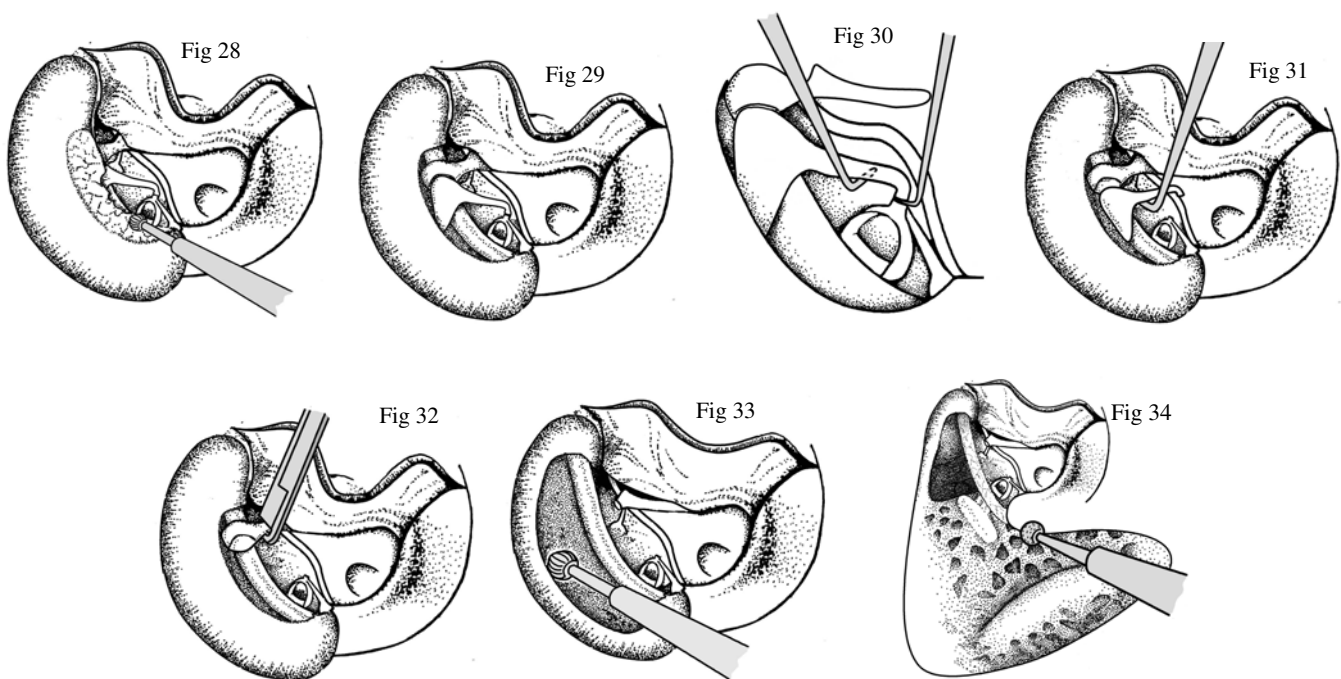
### **Attico-antrostomy**

The purpose of this exercise is to introduce you to the “front-to-back”, “inside out”, “attico-antrostomy”, or “disease-pursuant” approach to cholesteatoma surgery. The principle is that, in dealing with squamous epithelium going superiorly or posteriorly under bony scutum, one has no idea how extensive it is. By following the disease out and letting it dictate the extent of bony removal, the extent of the resulting atticotomy or mastoid cavity is always exactly appropriate to the disease, and cavity size is thus always minimised.

- Lift a tympanomeatal flap from 2 – 6 o’ clock (R ) or 10 – 6 o’ clock (L) providing standard postero-superior access (Fig 22).
- Dislocate the annulus from its sulcus to enter the middle ear. This is usually done inferiorly to avoid damaging the chorda and ossicular chain. Then elevate it inferiorly, to 6 o’ clock then superiorly, looking out for chorda tympani.
- Displace the flap forward. See what access you get to the posterior mesotympanum (Fig 23, 24).
- From now on the extent of the surgery in a patient depends on the extent of the disease. Let’s begin by imagining squamous epithelium extends postero-superiorly, under the scutum.
- One then needs to remove postero-superior scutum, to follow disease out.
- First, elevate canal skin more antero-superiorly: (Fig 25)
- Now start enlarging the postero-superior aspect (10-3 o’ clock L, 9-2 o’ clock R) of the bony external auditory canal from outside inward with a large cutting burr (Fig 26). With each burr, go as deep as you can without damaging the canal skin. Use your sucker to displace the cut off external auditory canal skin antero-inferiorly.
- Change to a smaller burr and take it down to a deeper level, leaving a protective ledge of bone over the scutum, protecting chorda and the ossicles (Fig 27).



- “Eggshell” the scutum (Fig 28).
- Change to 2mm cutting burr or curette and remove the eggshelled bone to expose the incus body and the head of the malleus without touching them or any part of the ossicular chain (Fig 29).
- Examine the ossicular chain, and imagine assessing whether squamous epithelium proceeds medial to the ossicles; and whether the incudo-stapedial joint is intact or eroded.
- Let’s imagine squamous epithelium is medial to the incus. It then needs to be removed.
- Dislocate the I-S Joint (Fig 30), and dislocate the incudo-malleolar joint by lifting the incus long process laterally (Fig 31). Remove it.
- Now imagine disease goes medial to malleus head.
- Use the malleus nipper to amputate the malleus head goes just superior to the lateral process, corda and tensor tympani (Fig 32). Remove malleus head. Note the horizontal portion of the facial nerve beautifully exposed.
- Now imagine you can see a sac extending up into the attic, which you need to follow out to its full extent.
- Remove bony scutum from medial to lateral, increasing the size of your “atticotomy”. Do this superiorly, posteriorly and anteriorly (Fig 33). When appropriate, change to a larger burr. Also bring the bony removal out laterally, making access easier. Pretend cholesteatoma fills the entire anterior, superior and posterior attic, so expose the whole attic.
- Now imagine that the squamous sac extrudes through the aditus into the antrum. Remove bone posteriorly to uncap the aditus and antrum and eventually the mastoid air cell system.
- Finally, complete the “front-to-back” modified radical mastoidectomy (Fig 34). Lower the facial nerve ridge. It should be low enough laterally so that a line of vision from the floor of the external auditory canal has unobstructed sight into the cavity. Take down the anterior buttress to have a rounded self-cleansing cavity.

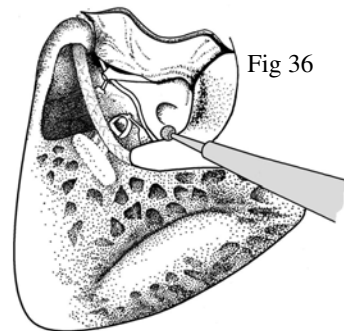
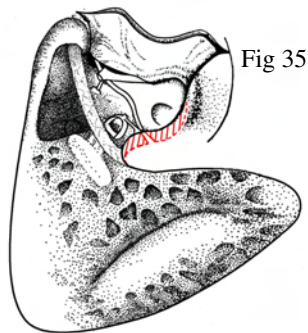


More senior dissectors may wish to practice.....

### Dealing with posterior mesotympanic cholesteatoma

Let us assume the squamous sac lies hidden in the facial recess and sinus tympani, deep to posterior bony scutum.

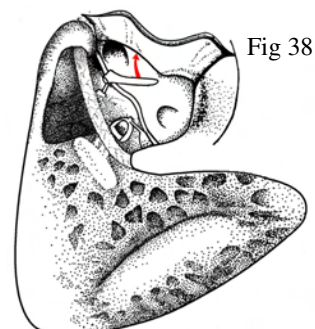
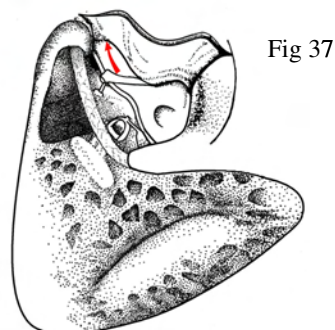
- Focus on the area of the “otologic jackpot”, between chorda tympani, (laterally), stapes in oval window, facial nerve and lateral semi-circular canal (medially).
- Note that by identifying facial nerve, it is possible with a 2mm diamond to remove bone between chorda and facial nerve, inferior to the fossa incudis and inferior-lateral sac (Fig 35).
- By drilling on both sides of chorda, this access can be increased considerably, essentially down to chorda’s origin from the facial nerve (Fig 36).
- Observe how you obtain exposure of the facial recess, stapedius tendon, pyramidal process, and round window niche.
- You can imagine how this can allow a squamous sac to be dissected intact from the posterior mesotympanum.



### Dealing with anterior mesotympanic cholesteatoma

Imagine now that squamous epithelium extends forwards under the malleus into the anterior mesotympanum.

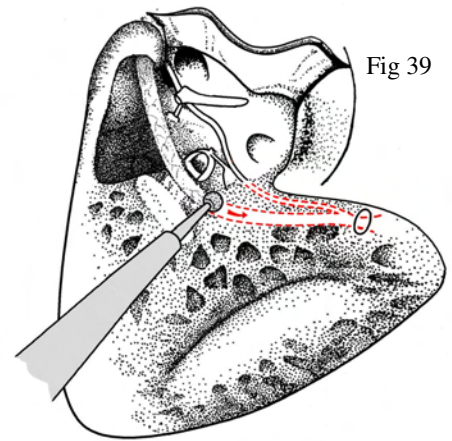
- Dissect the tympanic membrane down off the malleus handle (Fig 37).
- Displace the eardrum forwards (Fig 38).
- See how access is gained to the anterior mesotympanum and around the malleus handle and tensor tympani – and even the mouth of the eustachian tube.
- See also how squamous epithelium might be dissected out of the hypotympanum.



## Explore the facial nerve

This exercise demonstrates the vertical/mastoid segment of the facial nerve.

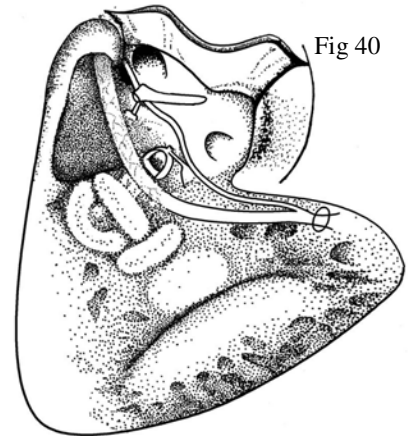
- Identify the facial nerve in its horizontal portion and at its window/stapes
- Progressively uncap the nerve in its vertical portion, with stylomastoid foramen (Fig 37).
- Use even drill strokes, with a largish (4mm) burr, and go when close to the nerve.



More senior dissectors may wish to.....

## Expose the semicircular canals (Fig 40).

- Use gentle “burnishing” drill strokes, diamond burrs and good irrigation
- Start by defining the lateral canal
- Use the 4 mm rule to outline the posterior canal
- Then expose the superior canal.



Thereafter if there is time

## Blue line the semicircular canals

- Using a diamond, remove bone until the membranous semicircular canals can be seen through the paper-thin bone.

Thereafter if there is time

### **Labyrinthectomy (Fig 40)**

This exercise take you through performing a labyrinthectomy, which is also part of preparation for the translabyrinthine approach to the internal acoustic canal.

- With a wide mastoidectomy and atticotomy, and the 2<sup>nd</sup> genu and vertical portions of the facial nerve visible, you are well placed to proceed.
- Start with the lateral semicircular canal. Start with its posterior end, then its anterior portion, which is close to the facial nerve – be careful.
- The anterior end leads you to the anterior part of the superior semicircular canal. Follow this posteriorly under the dural plate (the subarcuate eminence)
- Now follow the posterior semicircular canal from posterior to anterior – again being careful where it goes deep to the descending facial nerve anteriorly.
- Now remove the membranous canals and open the vestibule - particularly posterior and medial to the 2<sup>nd</sup> genu of the facial nerve.

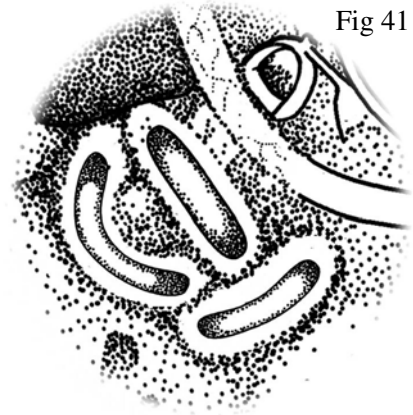


Fig 41

Finally, if there is time

### **The Translabyrinthine approach to the Internal Acoustic Canal**

## Day 3: Bone 1

### Ossiculoplasty

This exercise equips you to deal with the commonest ossicular chain deficiency; of the bony process of the incus.

- Disarticulate the incudo-stapedial joint
- Dislocate the incudo-malleolar joint
- Tease the incus down and remove with forceps
- Fashion the incus by drilling to create a prosthesis. There are various techniques you may choose between. 3 are illustrated (Figs. 44, 45, 46).
- Insert the prosthesis and check its correct size
- Replace the tympanomeatal flap

Fig 44

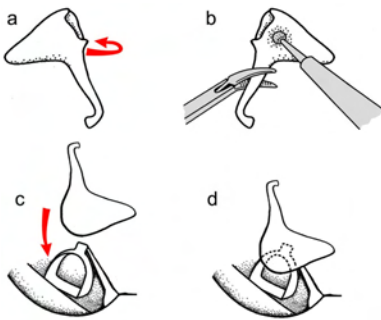


Fig 45

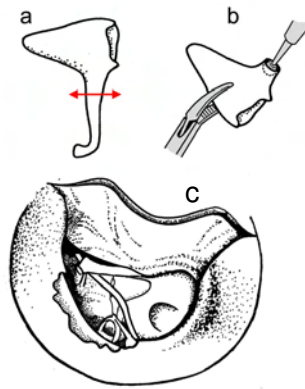
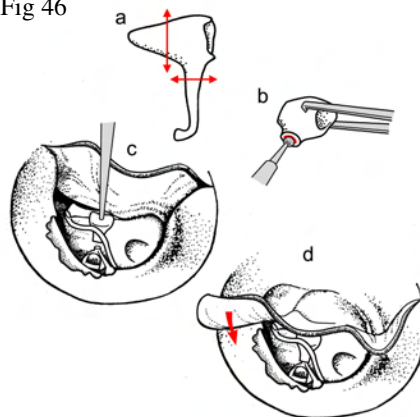


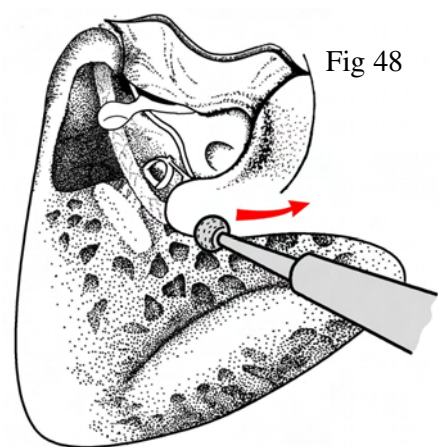
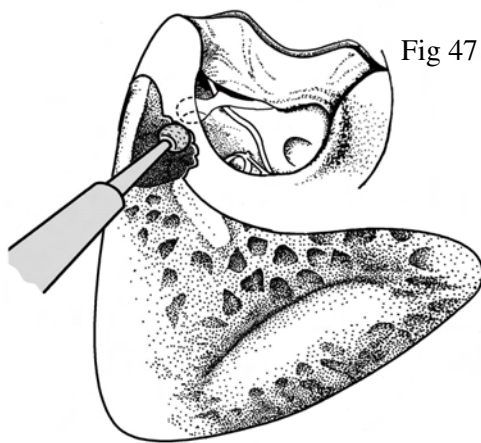
Fig 46



Thereafter the more junior surgeons should

### Create a modified radical mastoidectomy

- Gradually drill down the posterior canal wall until you are left with a bridge over the incudal fossae and the malleus (Fig 47).
- Either curette away this bridge or very carefully remove it by drilling. The danger is going through it and damaging the facial nerve.
- Remove any anterior buttress.
- Using a medium diamond burr, continuous irrigation, and strokes parallel to the facial nerve, lower the posterior canal wall and the facial ridge as far as possible, leaving only a thin plate of bone covering the facial nerve (Fig 48).
- Cut the external auditory canal skin through antero-superiorly from lateral down to the tympanic membrane, and lay it over the facial ridge.



**The more senior surgeons should perform any procedure that they have not previous performed the previous day on the other bone.**

Alternatively

### Identification of the internal carotid artery

- This lies just anterior and medial to the Eustachian tube orifice.
- Position yourself to have access to the anterior mesotympanum.
- Lower the anterior bony annulus to fully expose the Eustachian tube orifice.
- Using a diamond burr drill anterior and medial to it to expose the internal carotid artery