

FOREIGN BODIES IN ENT

Tygerberg Hospital

Marize Viljoen

Division of Otorhinolaryngology
Faculty of Health Sciences
Tygerberg Campus, University of Stellenbosch

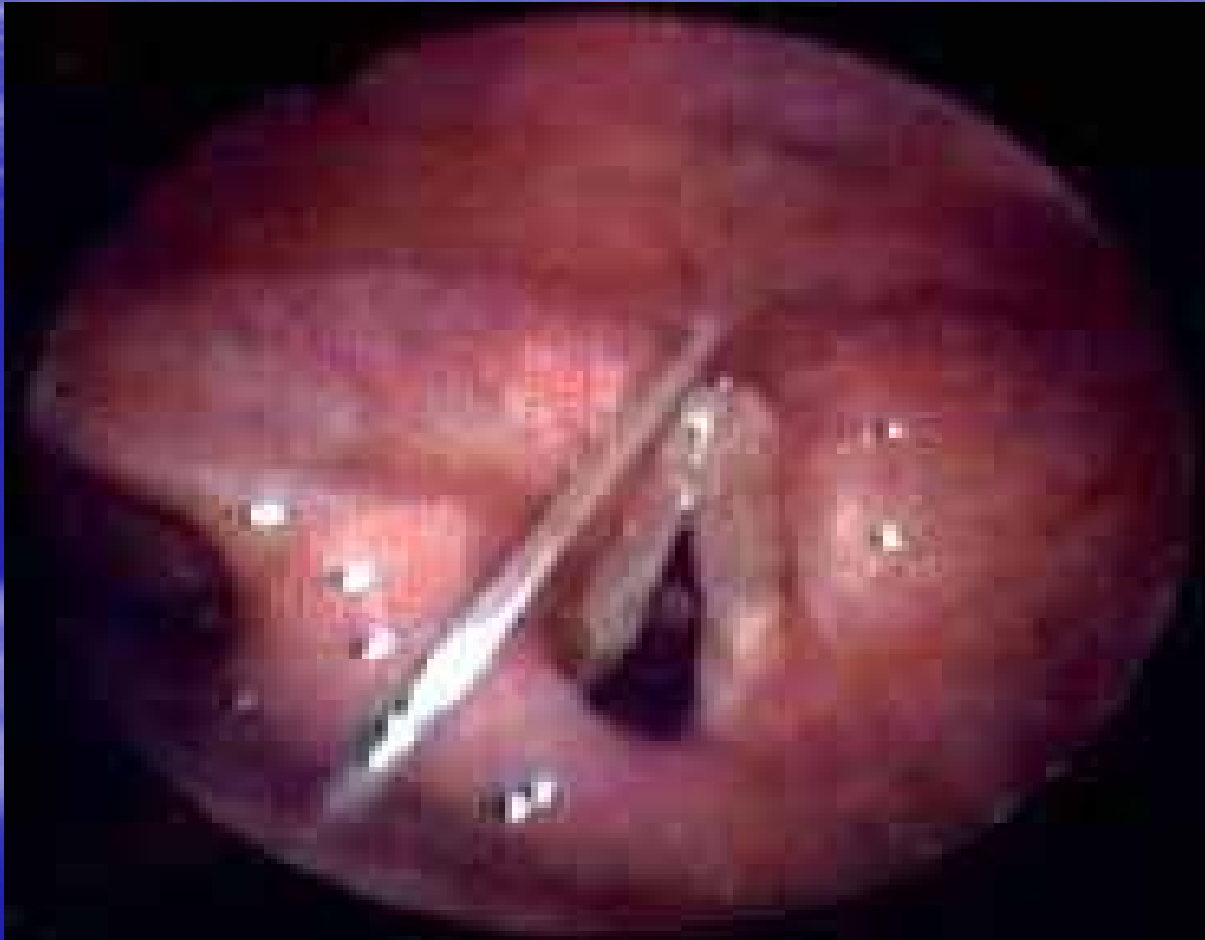Airway (Larynx+Trachea):

- Usually inhalation *Adult – anaesthesia, asleep/ drunk
- *Child – frightened to mention (suspicion)
- Most common 1-3yrs all ages
- M:F 2:1
- Objects: Nuts, Seeds, Sweets, Toys

Larynx

- Larger objects
- Acute respiratory distress
- Symptoms: Hoarseness/aphonia, stridor, dyspnea, salivation, perichondritis, stenosis
- Rx: 1) Heimlich manoeuvre
2) Removed under direct laryngoscopy
3) Tracheostomy/ laryngotomy

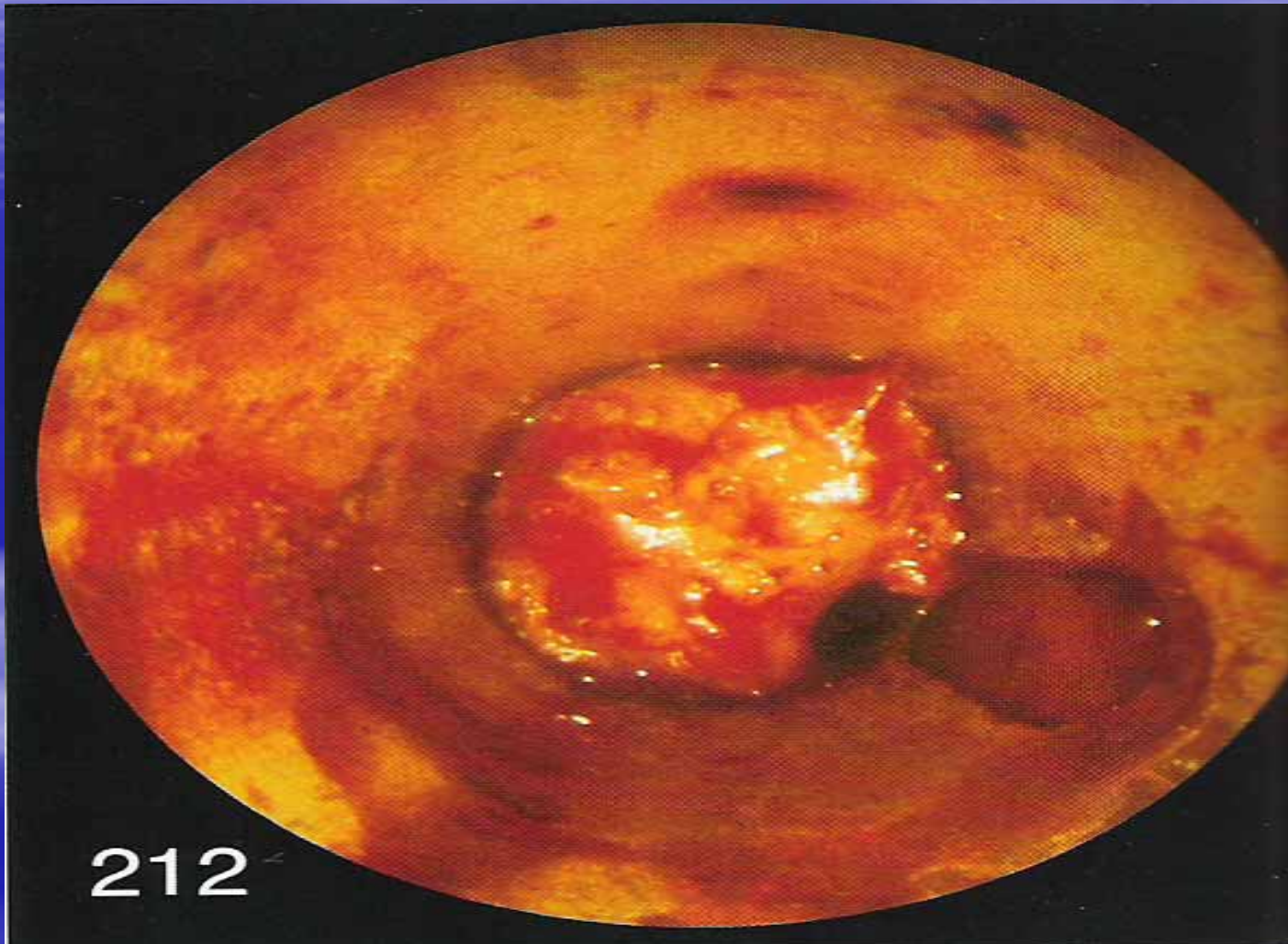
Fish Bone



Trachea

- Smaller objects down trachea
- Symptoms more subtle
- Sx: Choking, coughing, wheezing
- Lodge in R main bronchus
- Sx: Unilateral exp wheeze, low air entry, granulation tissue, atelectasis, lobar pneumonia, lung abscess

Peanut in trachea:



Rx in Trachea

- Rigid bronchoscope + grasping forceps
- Thoracotomy/ bronchotomy
- Granulation tissue- 10% adrenaline solution
- Distal bronchial tree- aspirated
- Second look sometimes required
- Antibiotics + Lung physiotherapy

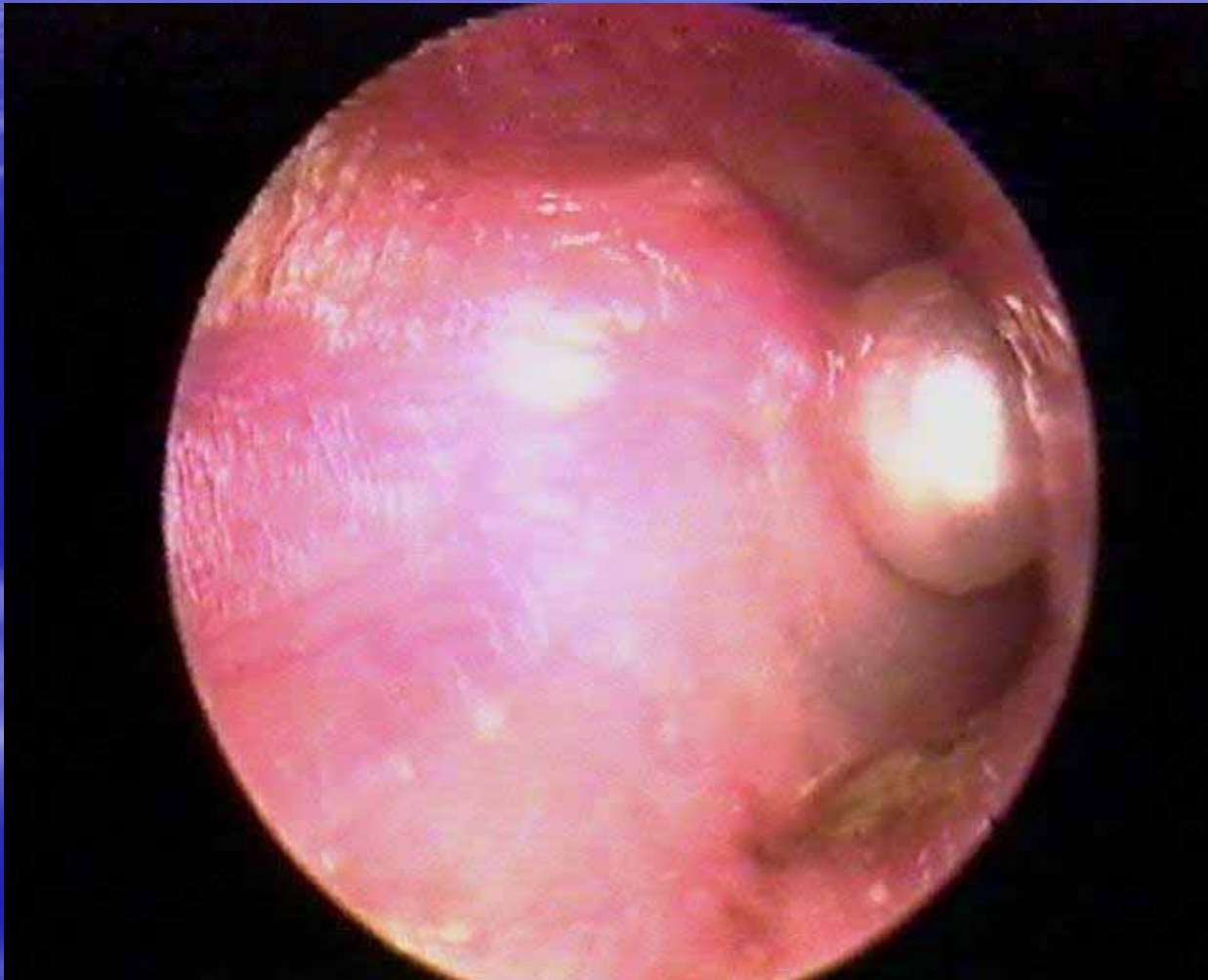Ears

- Most common site in ENT
- Types: Vegetable/ non-vegetable/ live insects
- Results 1)Trauma to EAC
2)Perforation of eardrum
- Sx: Intense irritation, noise, tinnitus, conductive deafness, otalgia, reflex cough
- Rx: *Direct vision- syringing/ suction, hooks(beads/ stones), magnet(ferrous), forceps(CI), GA!!

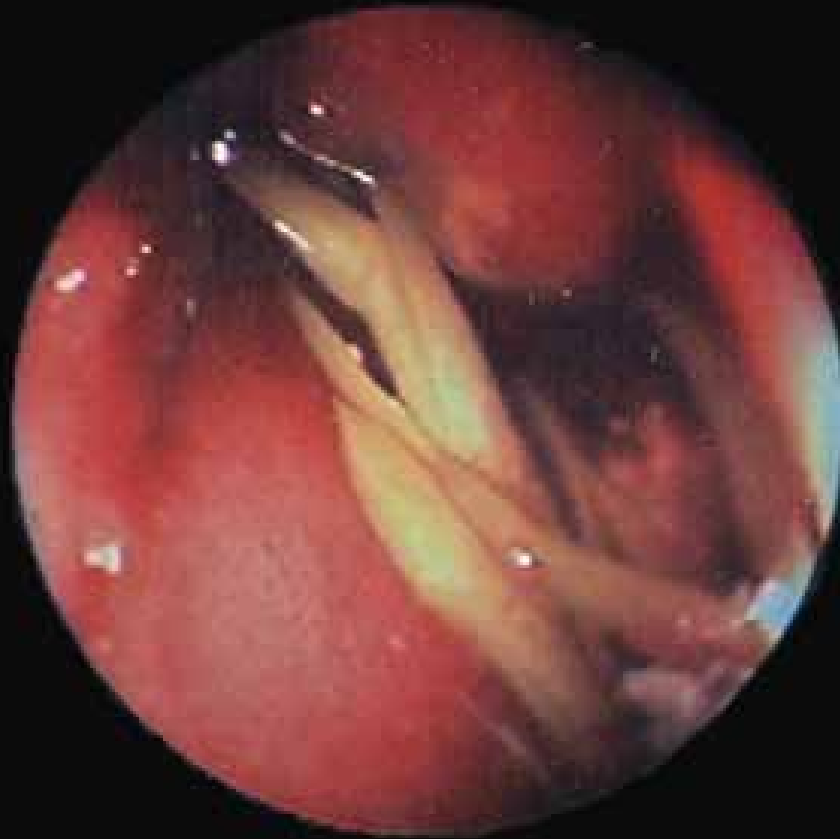Nose

- Routes –ant. nares, post choanae, penetrating wounds
 - Pebbles, peas, rubber, plastic objects, seeds
 - Sx:Foul unilateral D/C, obstruction, pain, sneezing, nose bleeding, atrophy of mucous membrane
 - Rx:1)Forcible nose blowing
- 2)Direct vision- fine nasal forceps/ hook
- 3)Rigid telescope- post/ high in nose

Lt Nostril:



Rt nostril



Oesophagus + Pharynx:

- Accidentally/ Diet
- Food bolusses, coins, bones (fish/chicken), plastic/ metal toys, sweets
- Strictures (pathology/lesions /burns); decreased motility
- Sx: Discomfort, pain, dysphagia, incontinent of saliva, swelling, dyspnea, hoarseness
- Sites: Tonsil; Valleculae; Cricopharyngeus

Treatment:

- 1) X-ray lat neck + AP (soft tissue), IV fluids + Buscopan
- 2) Rigid oesophagoscopy in theatre
- 3) External cervical oesophagectomy/
thoracotomy

The End

