

Otalgia

Dr Karen Lehmann

Division of Otorhinolaryngology

University of Stellenbosch and Tygerberg Hospital

Otalgia

- Otalgia is the symptom of pain in the ear
- Origin classified as:
 - Otological: 50%
 - Referred: 50%

Sensory nerve supply

- Cranial nerves:
 - V₃
 - VII
 - IX
 - X
- Cervical plexus:
 - C₂
 - C₃

Association with other symptoms

- Hearing loss
- Otorrhoea (complicated cholesteatoma)
- Systemic symptoms (fever, malaise)
- Dermatological changes (pinna, external ear canal, tympanic membrane)
- Odynophagia/dysphagia

Establishing an otological cause

Examine:

- External ear canal/pinna
- Tympanic membrane

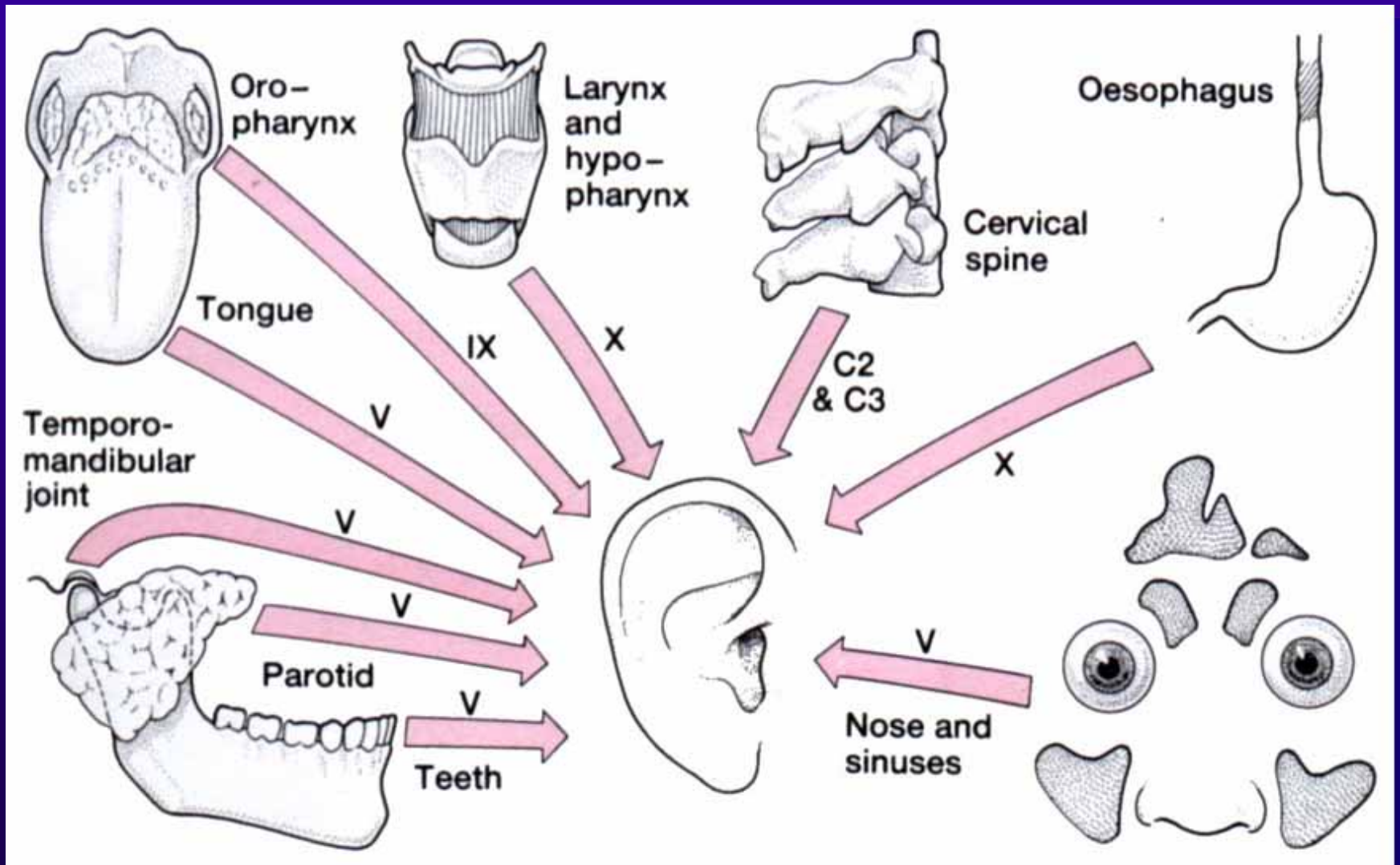
If necessary:

- Remove debris to see tympanic membrane
- Carefully remove wax

Otological examination normal

Possible causes of referred pain:

- Temporomandibular joint
- Teeth/dentures (ill fitting)
- Nasopharynx
- Hypopharynx
- Cervical spine
- Esophagus

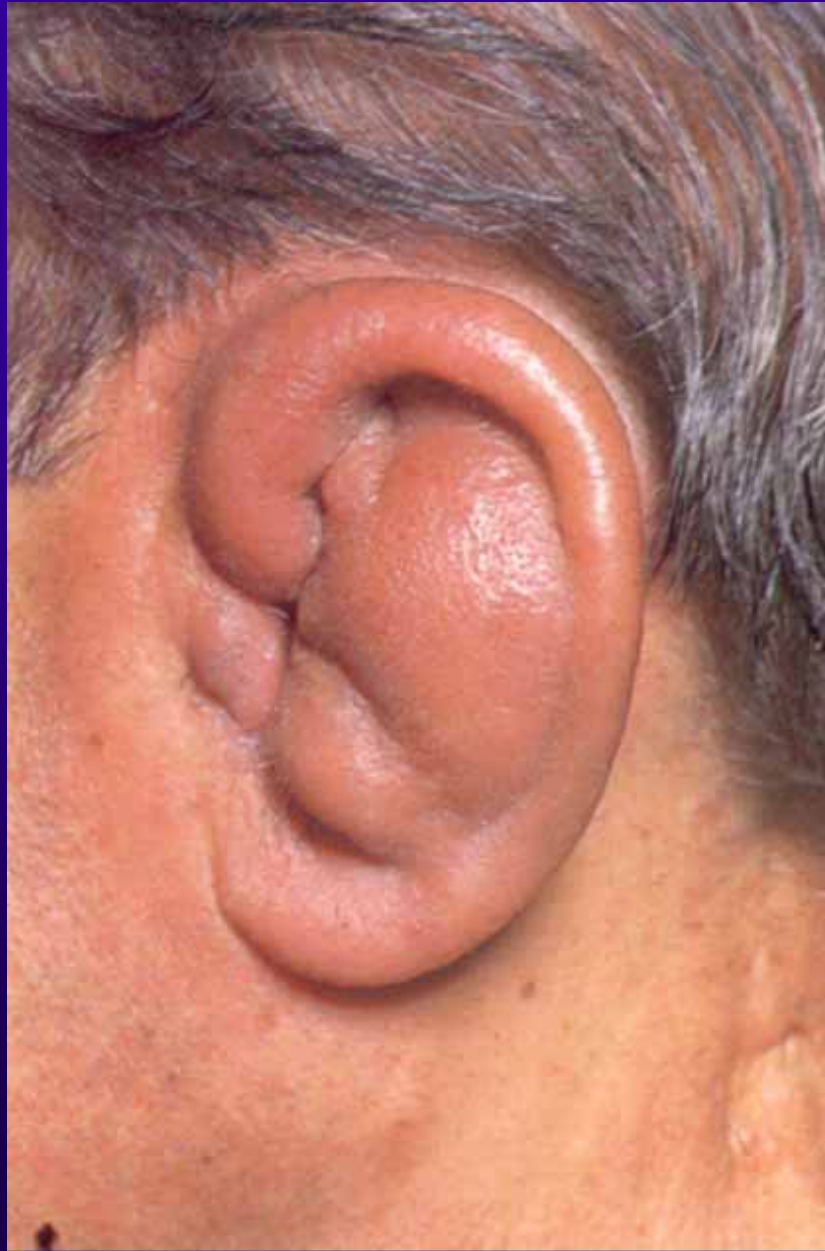

Otological causes

- (A) External ear
- (B) Middle ear
- (C) Traumatic

(A) External ear

- Dermatological pathology may be obvious
 - Tenderness elicited on movement of pinna
 - Swollen external ear canal
 - Tympanic membrane often not visible



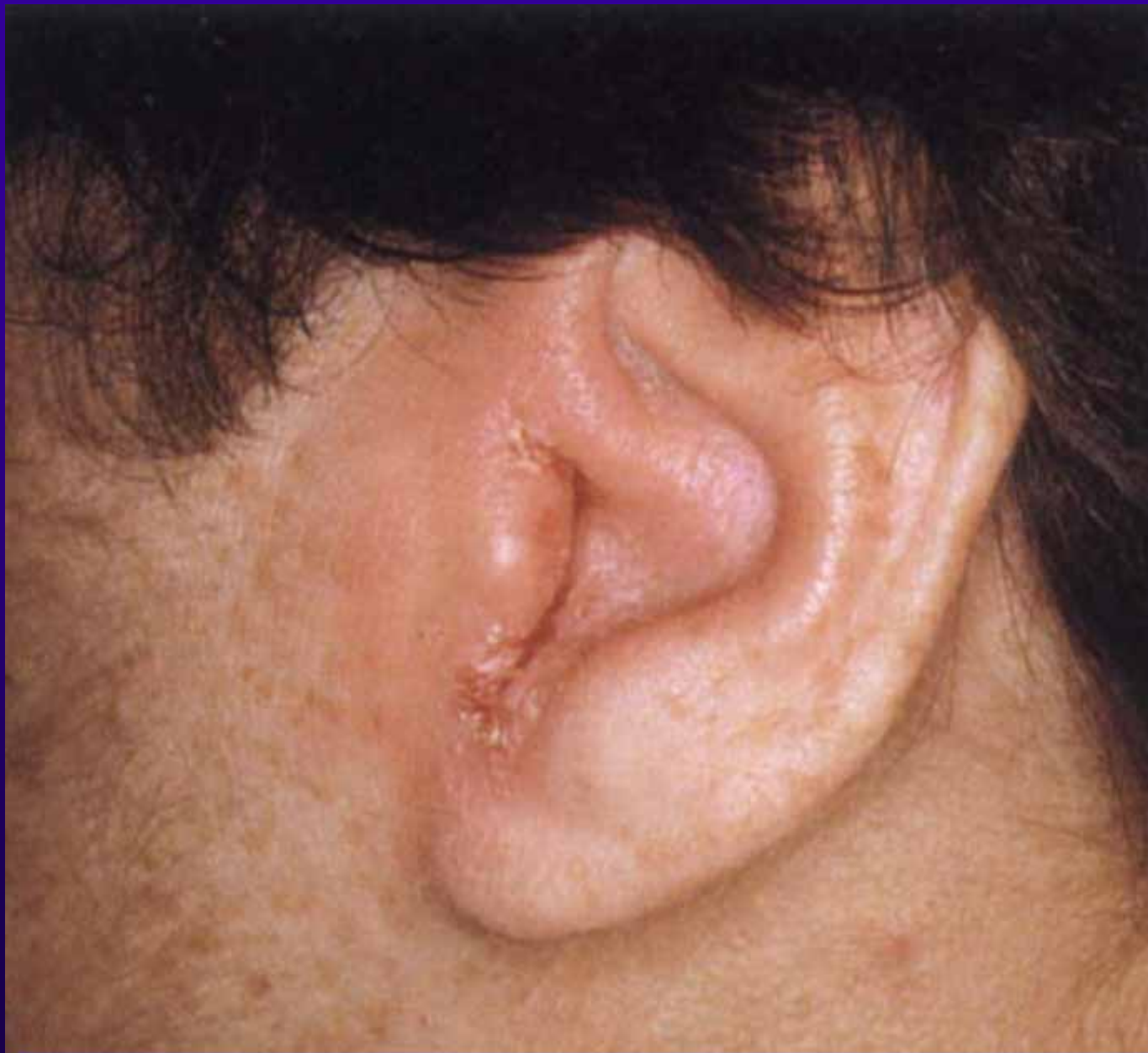Examples (external ear)

Otitis externa:

- Severe otalgia
- Variety of causes
- May have a malignant variety
- Degrees of skin involvement

Treatment:

- Analgesics
- Antibiotic/steroid drops



Examples (external ear) *continued*

- Ramsay-Hunt syndrome: vesicles
- Meatal Furunculosis
- Erysipelas/Cellulitis

Treatment:

- Analgesics
- Antibiotics
- Anti-virals

(B) Middle ear

- Otolgia present as long as tympanic membrane is intact
- The onset of otorrhoea usually ends the otalgia
- Otolgia developing in association with chronic otorrhoea signals a complication
- Important to visualize the tympanic membrane

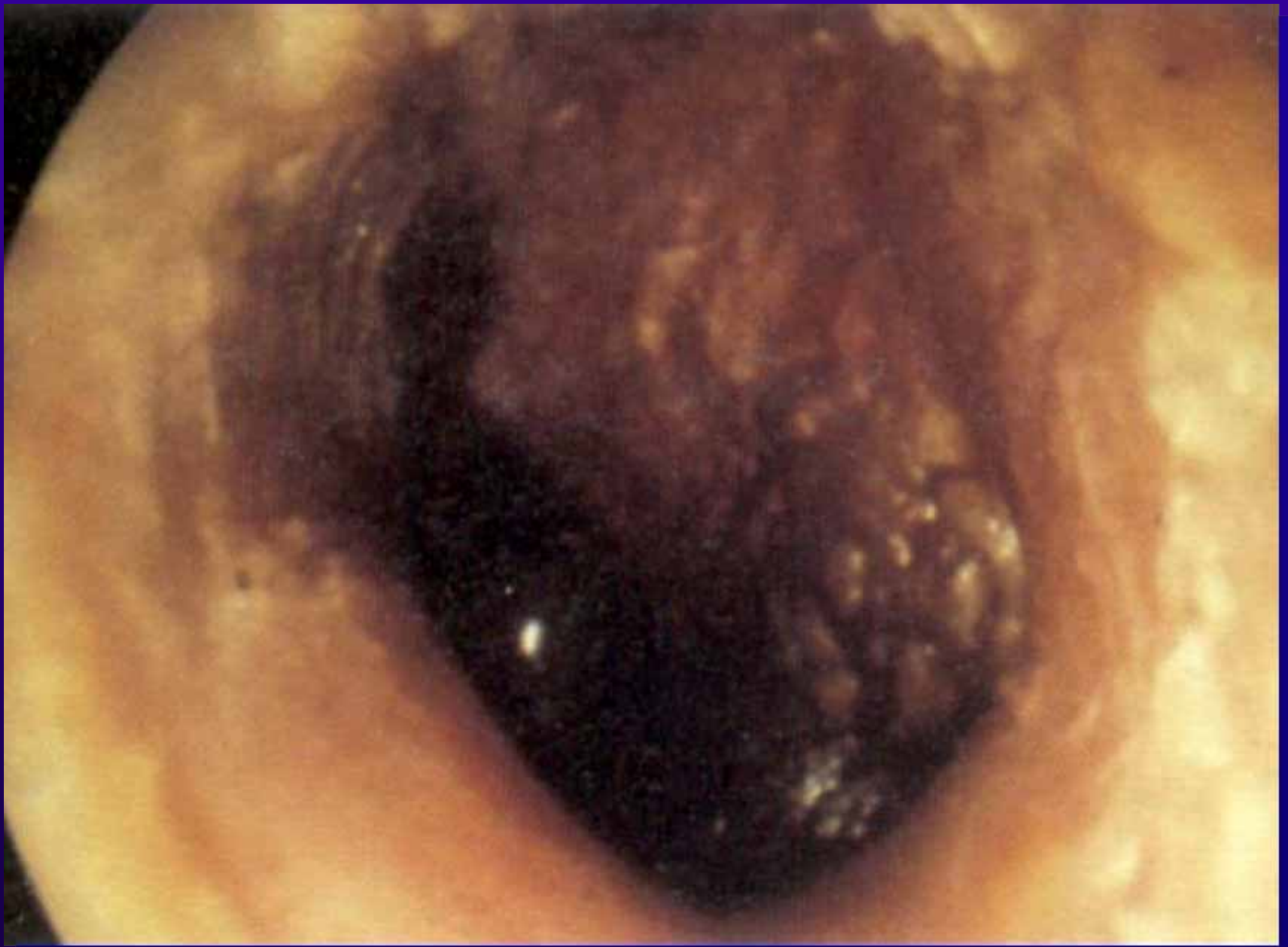
Examples (middle ear)

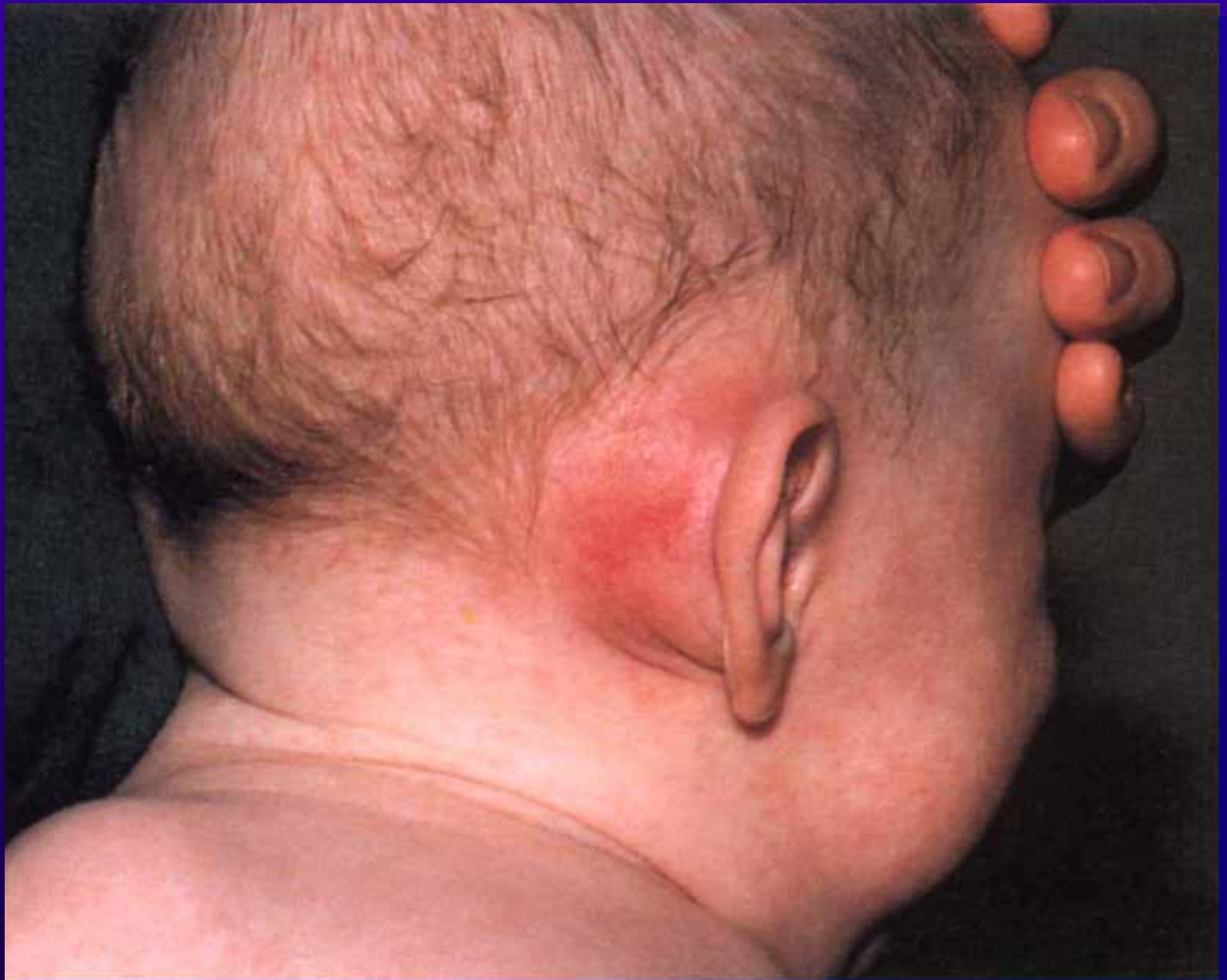Acute otitis media:

- Common in childhood
- Systemic symptoms (fever, malaise)
- Bulging, red tympanic membrane
- Perforation results in resolution of otalgia

Treatment:

- Analgesics
- Oral antibiotics





Examples (middle ear) *continued*

Myringitis Bullosa:

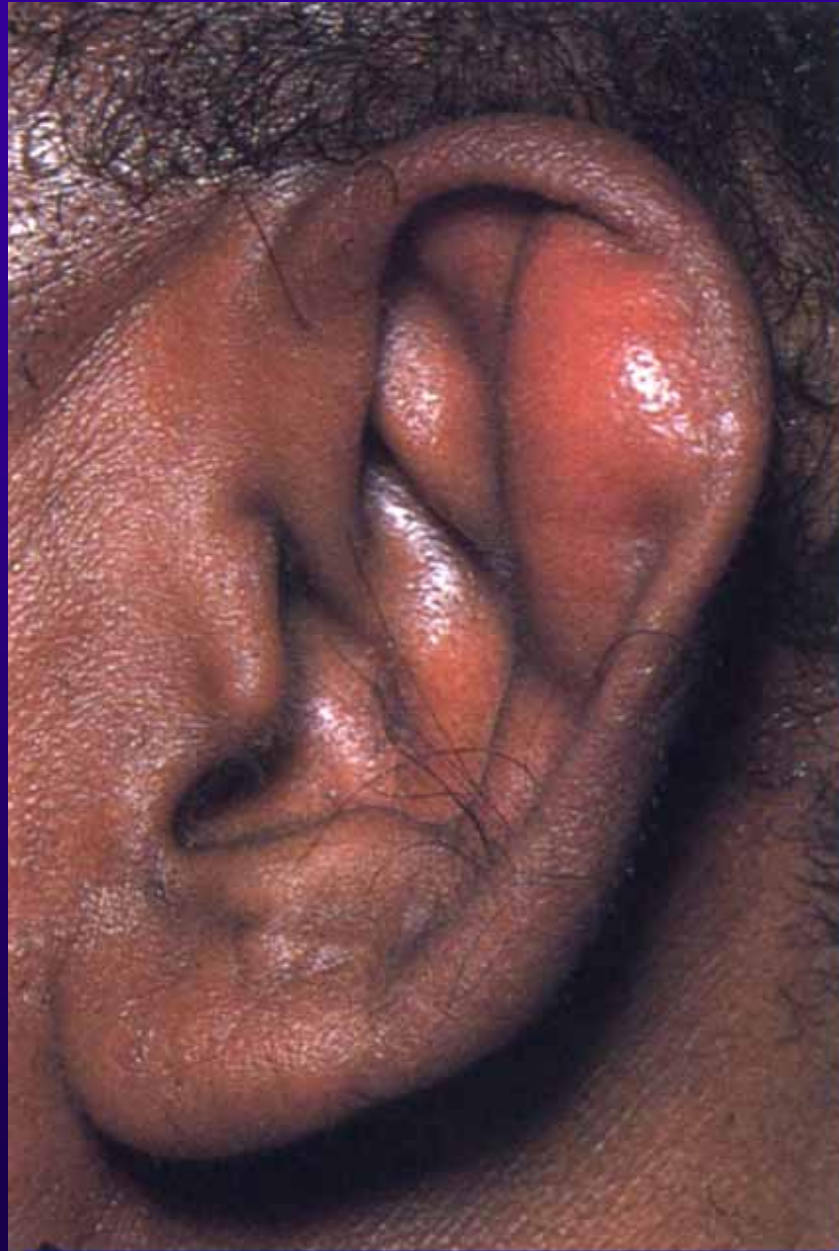- Unknown origin
- Bullae on tympanic membrane
- May be haemorrhagic or serous
- Both ears often involved

Treatment:

- Analgesics
- Topical antibiotic/steroid drops

(C) Traumatic

- Direct trauma to middle ear via foreign body
- Barotrauma
- Temporal bone fracture
- External ear: haematoma



Referred pain

- More commonly found in adults
- Normal examination of the ear excludes otological causes
- Temporomandibular joint causes are the most common

Referred pain *continued*

Temporomandibular joint:

- Crepitus on examination of TM joint
- Ill fitting dentures and dental problems should be excluded

Treatment:

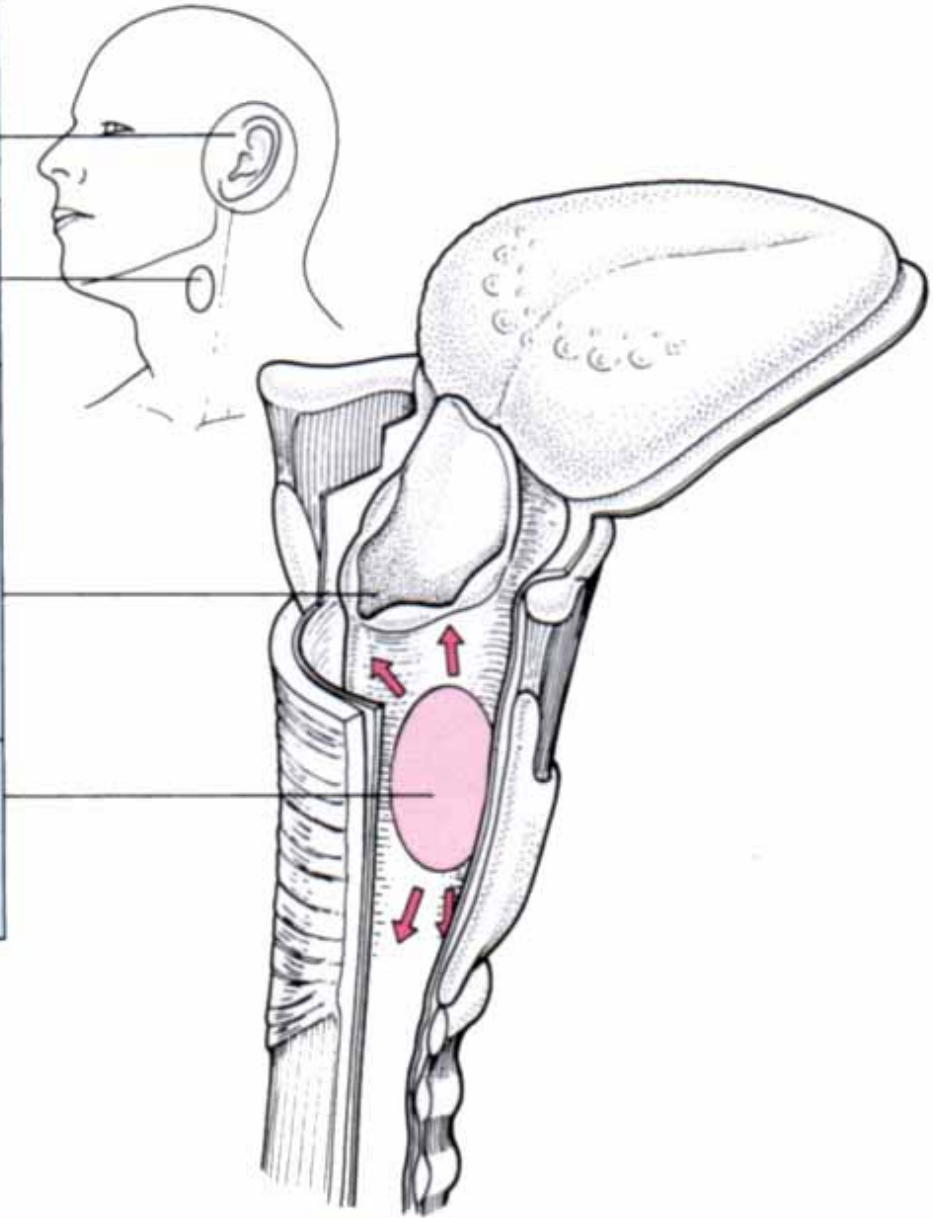
- Refer to maxillo-facial surgeon

Referred pain *continued*

Hypopharyngeal pathology:

- Patients presenting with dysphagia and otalgia have hypopharyngeal carcinoma until proven otherwise
- Indirect laryngoscopy will reveal any pathology
- Otalgia indicates perineural spread and a bad prognosis

Symptoms
Otalgia
Enlarged neck node
Dysphonia
Dysphagia and weight loss



Referred pain *continued*

Nasopharyngeal carcinoma:

- Naso endoscopy will reveal cause

Cervical pathology:

- Excluded by X-ray

Summary

- Otalgia from otological or referred origin
- Examination of the ear is very important and tympanic membrane has to be visualized
- If no otological cause is found, referred pain should be excluded
- Malignancy may be the cause