

TIPS FOR OTOSCOPY

James Loock

Division of ORL

Faculty of Health Sciences, U.S.

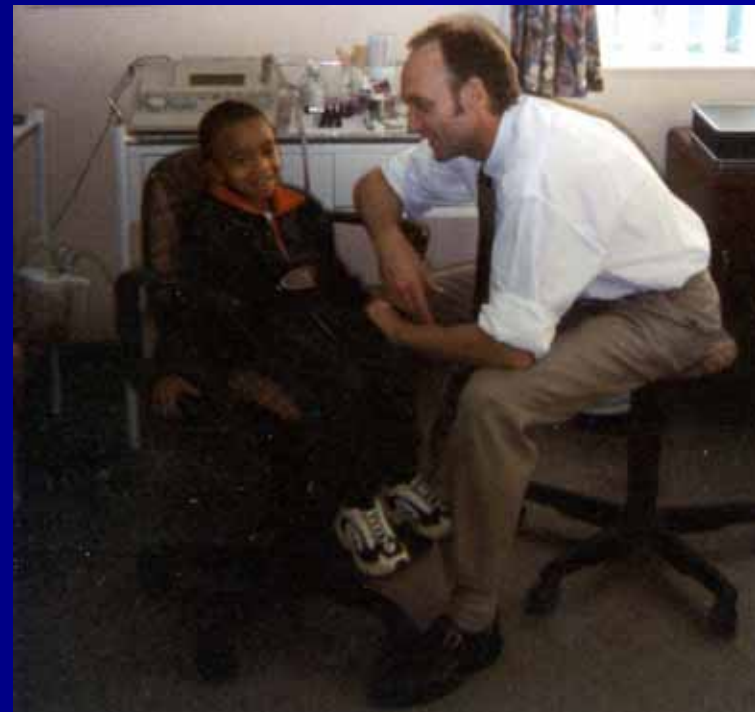Tygerberg Campus

The equipment

- Otoscope
- Light and battery
- Speculum
- Pneumatic bulb

Examination Technique

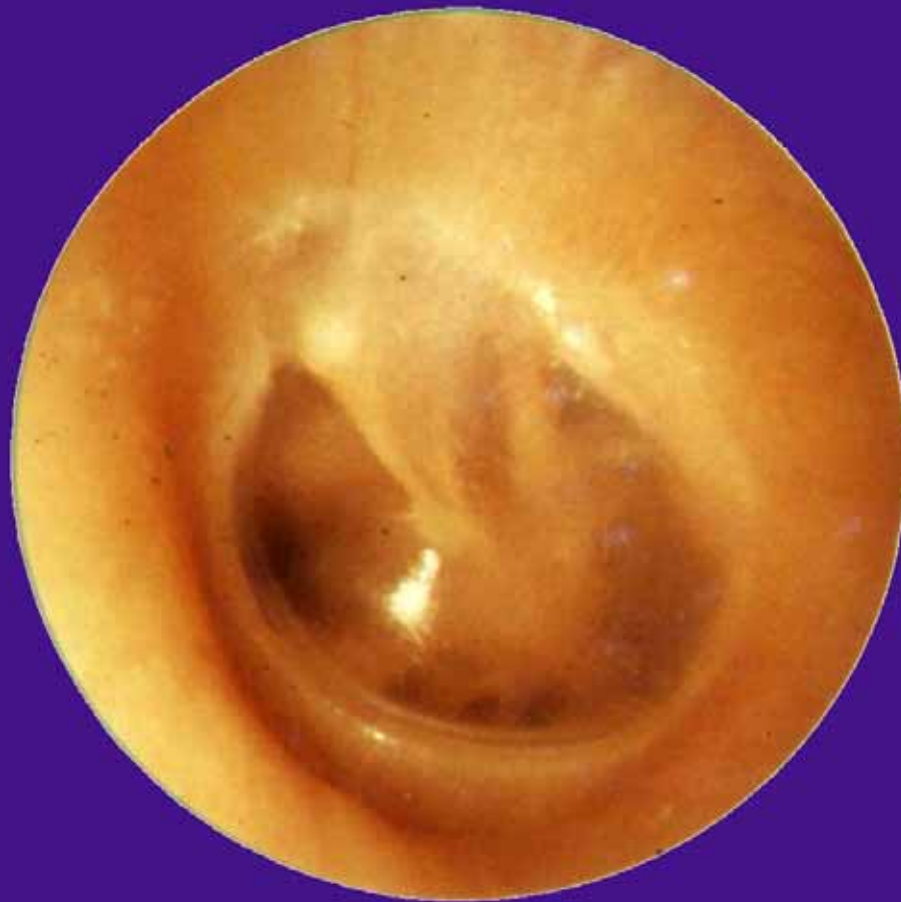- Positioning: patient vs examiner:
 - Comfortable seating
 - Turning head on shoulders
 - Height
 - Closeness
- Straightening canal
- Bulb



Dealing with wax

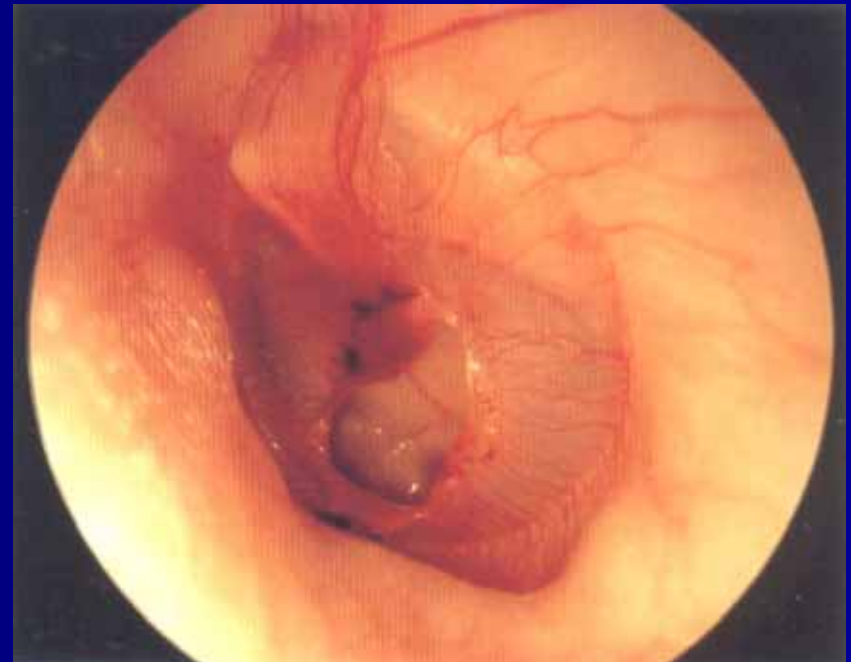
- Seldom obstructive: tympanometry
conductive h. loss
- "Teasing" it out
- Syringing: equipment
patience
first fill canal
dissolving it

The Normal Drum



Traumatic perforation of the eardrum:

- The dry perforation:
 - Avoid infection
 - Don't fiddle
 - Don't syringe
 - Don't give drops
 - High rate of healing
- The wet perforation:
 - Needs referring



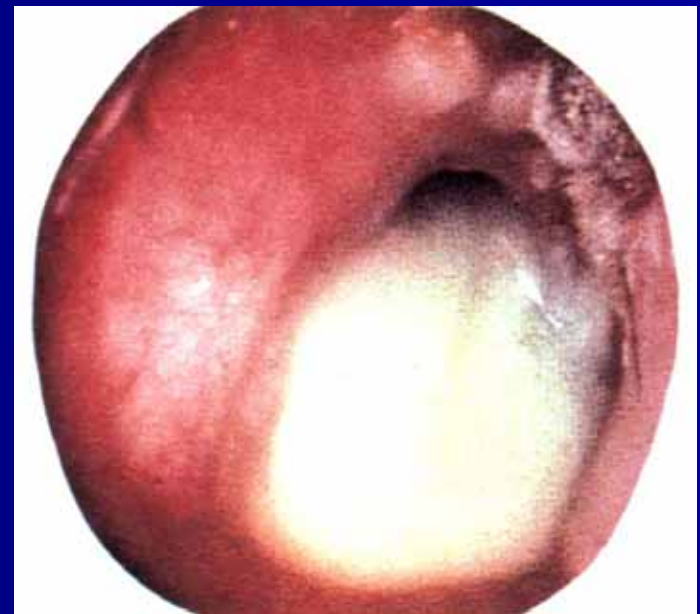The otitis medias:

- The Chronic Suppurative Otitis Medias
- Acute Otitis Media
- "Otitis media with effusion"/"Serous Otitis Media"/"Middle Ear Effusion"/"Glue Ear"

The otitis medias:

- The Chronic Suppurative Otitis Medias

Runny ear (otorrhoea)



– 3 causes: Intermittent:

Relentless:

infected perforation

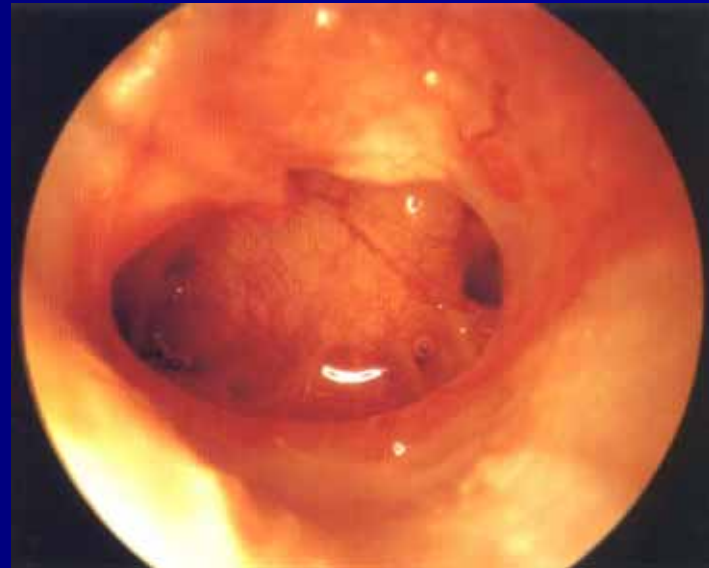
cholesteatoma

TB

The otitis medias:

- The Chronic Suppurative Otitis Medias

Runny ear (otorrhoea)



– 3 causes: Intermittent:

infected perforation

Relentless:

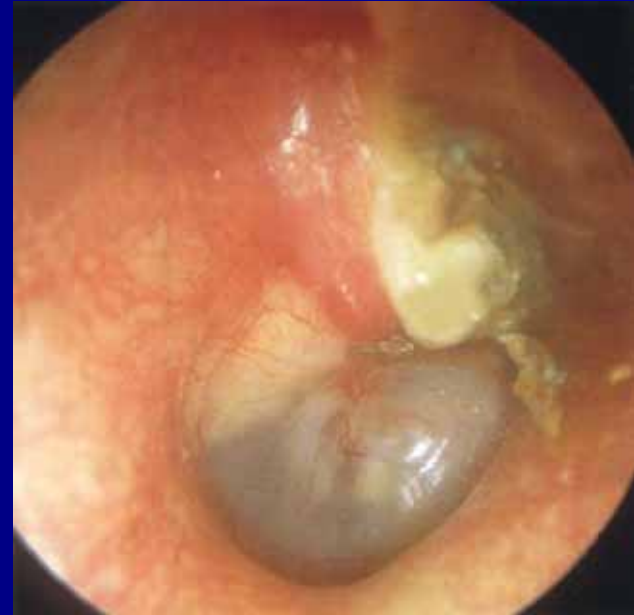cholesteatoma

TB

The otitis medias:

- The Chronic Suppurative Otitis Medias

Runny ear (otorrhoea)



– 3 causes: Intermittent:

Relentless:

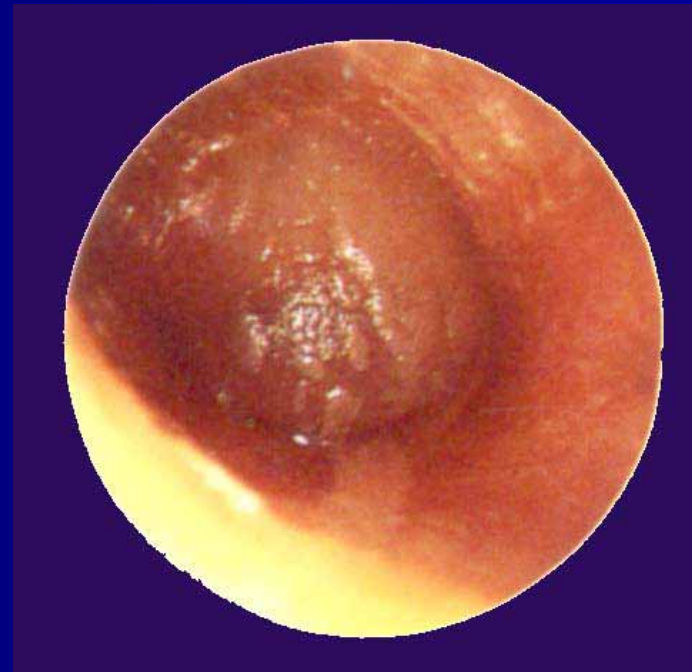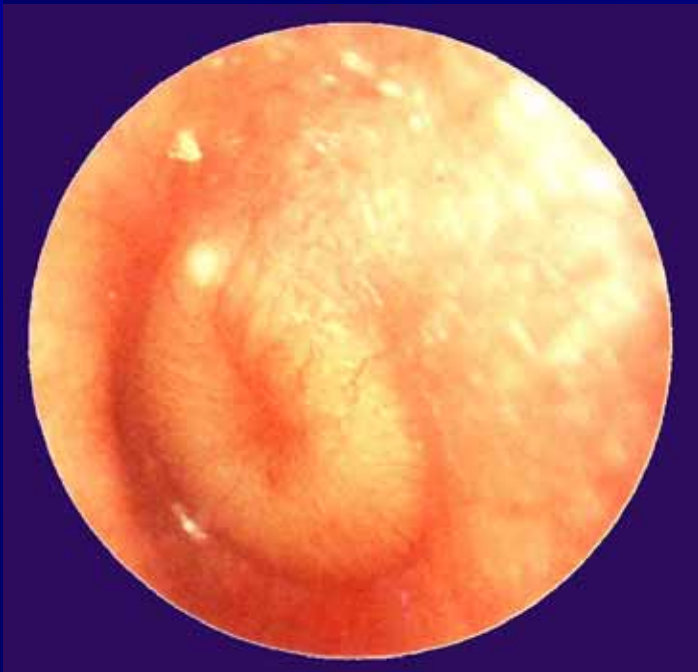
infected perforation

cholesteatoma

TB

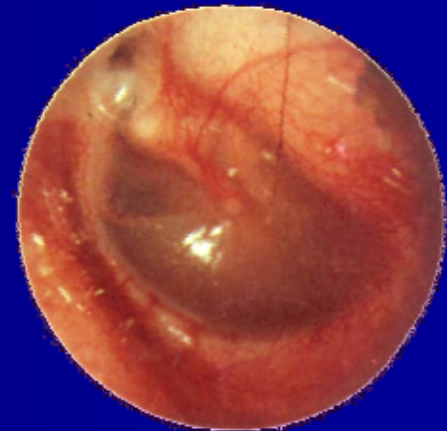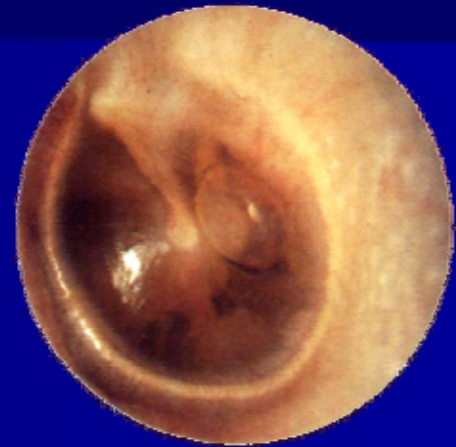The otitis medias:

- **Acute Otitis Media**
 - Ear pain
 - Inflamed (red) drum



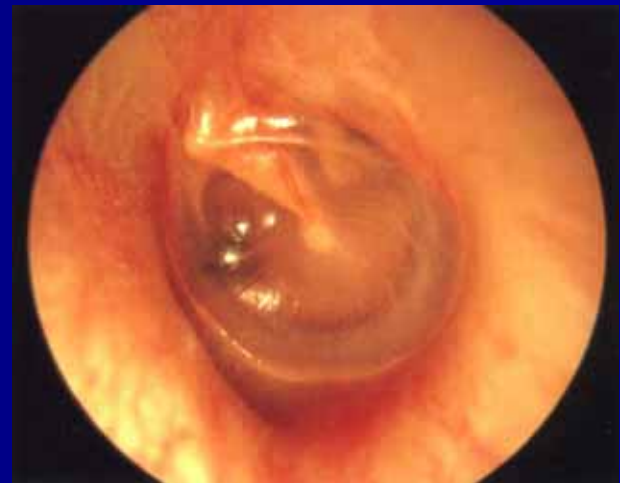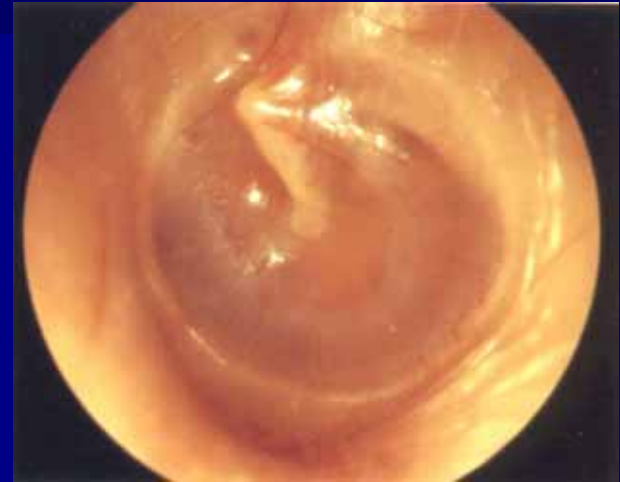The otitis medias:

- "Otitis media with effusion"
/"Serous Otitis Media"
/"Middle Ear Effusion"
/"Glue Ear"
 - No drainage
 - Intact drum
 - "Sterile" fluid behind drum
 - Variable appearance of drum
 - Mod. Cond. H. Loss
 - Tympanometry



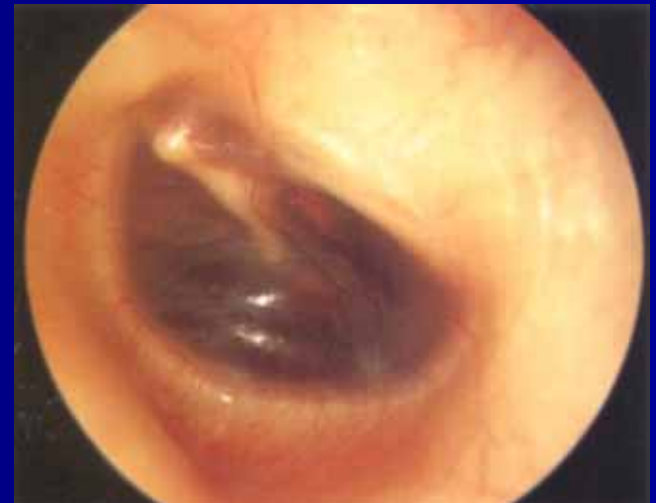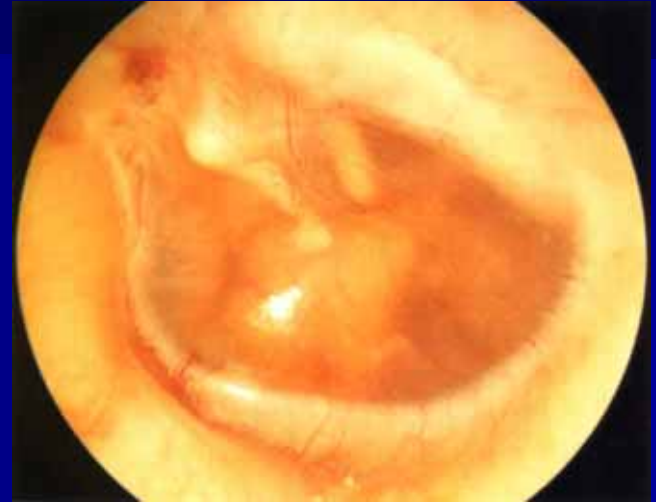The otitis medias:

- "Otitis media with effusion"
/"Serous Otitis Media"
/"Middle Ear Effusion"
/"Glue Ear"
 - No drainage
 - Intact drum
 - "Sterile" fluid behind drum
 - Variable appearance of drum
 - Mod. Cond. H. Loss
 - Tympanometry



The otitis medias:

- "Otitis media with effusion"
/"Serous Otitis Media"
/"Middle Ear Effusion"
/"Glue Ear"
 - No drainage
 - Intact drum
 - "Sterile" fluid behind drum
 - Variable appearance of drum
 - Mod. Cond. H. Loss
 - Tympanometry

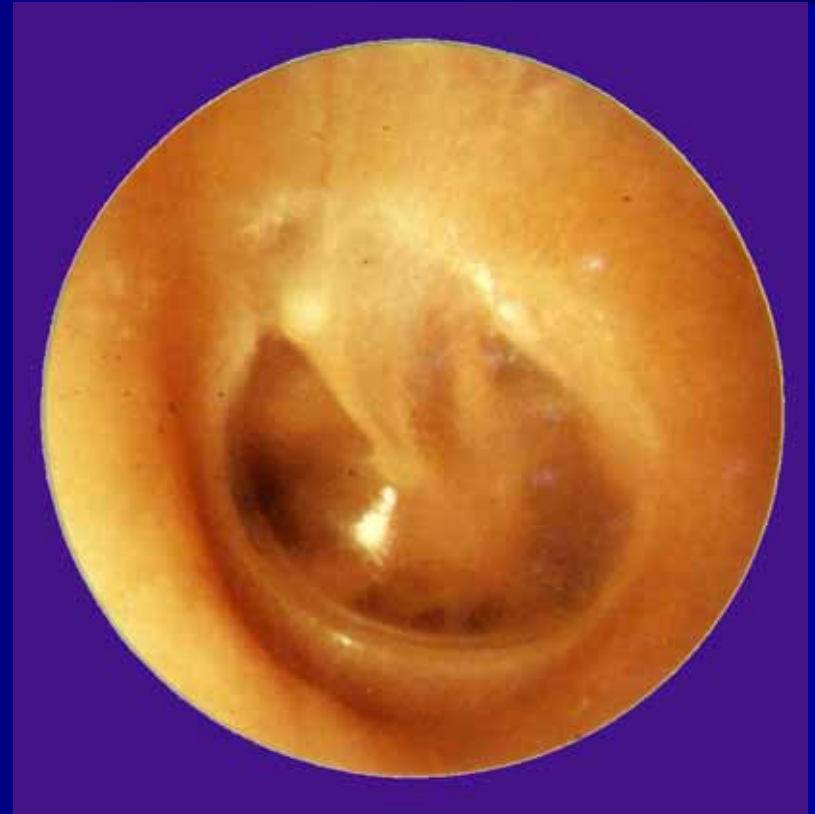

The otitis medias:

- The Chronic Suppurative Otitis Medias
- Acute Otitis Media
- "Otitis media with effusion"/"Serous Otitis Media"/"Middle Ear Effusion"/"Glue Ear"

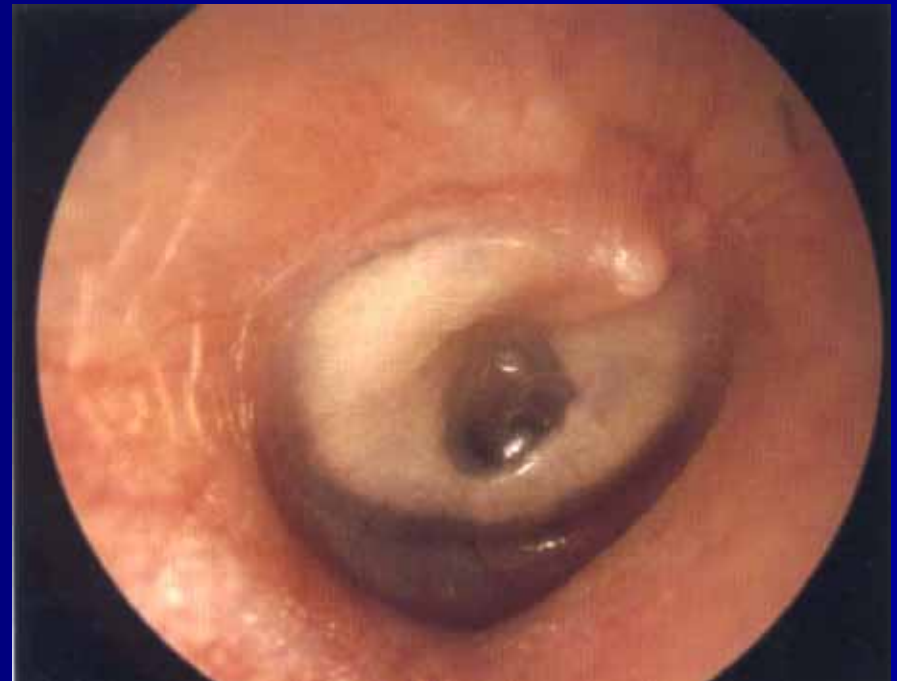Ear pain with a normal drum:

- Referred ear pain:
 - Jaw joint
 - Teeth
 - Mouth and throat
 - Glands in the neck



“Funny-looking eardrums:

- Tympanosclerosis
- Retractions
- Adhesive otitis media
- Other



“Funny-looking eardrums:

- Tympanosclerosis
- Retractions
- Adhesive otitis media
- Other

“Funny-looking eardrums:

- Tympanosclerosis
- Retractions
- Adhesive otitis media
- Other